

RD594  
89-4 F

A GUIDE  
TO  
OPERATIONS ON THE BRAIN

---

ALEC FRASER



EX LIBRIS  
JOHN FARQUHAR FULTON


Harvey Cushing / John Hay Whitney  
Medical Library

HISTORICAL LIBRARY



Yale University












A GUIDE  
TO  
OPERATIONS ON THE BRAIN







A GUIDE  
TO  
OPERATIONS ON THE BRAIN

ILLUSTRATED BY FORTY-TWO LIFE-SIZE PLATES IN AUTOTYPE  
AND TWO WOODCUTS IN THE TEXT


BY  
ALEC FRASER

PROFESSOR OF ANATOMY, ROYAL COLLEGE OF SURGEONS IN IRELAND



LONDON  
J. & A. CHURCHILL  
11 NEW BURLINGTON STREET  
1890





MS. A. 9.2  
534  
1845




TO THE MEMORY OF

MY DEAR FRIEND AND TEACHER

D<sup>R</sup> ALLEN THOMSON

I DEDICATE THIS BOOK





A.-I


B.-I



## CONTENTS.

	PAGE
A.—INTRODUCTORY . . . . .	1
B.—PERSONAL WORK . . . . .	2
I.—METHODS . . . . .	2
1. Preparation of the Heads	
2. Fixing the Tapes	
3. Embedding in Plaster of Paris	
4. Description of Apparatus for Serial and Composite Photography	
II.—TABLES SHOWING THE NUMBER OF ADULT AND YOUNG HEADS DISSECTED SERIALLY, WITH NUMBER OF NEGATIVES MADE OF EACH, AND ALSO OTHER PARTICULARS . . . . .	7
III.—DESCRIPTION OF THE SERIAL DISSECTIONS SO FAR AS THEY HAVE BEEN REPRODUCED . . . . .	8
IV.—DESCRIPTION OF THE RELATIONS OF THE DEEPER-LYING STRUCTURES TO THE SURFACE OF THE SCALP . . . . .	13
1. The Bone and chief Sutures	
2. The Dura, its chief Artery and the Lateral Sinus	
3. The External Surface of the Brain	
4. The Central Lobes and Lateral Ventricles	
5. The Inter, Mid, Hind, and After Brain, other Structures, and the Median Surface of the Fore-brain	
V.—SUMMARY AND GENERAL RULES . . . . .	20
VI.—BIBLIOGRAPHY AND SLIGHT HISTORY . . . . .	20
VII.—LIST OF PLATES, MADE FROM THE SERIAL AND COMPOSITE NEGATIVES, WITH DATE AND LENGTH OF EACH EXPOSURE, AND THE CIRCUMFERENCE OF EACH HEAD FROM WHICH THEY HAVE BEEN SELECTED . . . . .	23





the  
an  
po  
sci  
gre  
lim  
wo  
an  
  
evi  
  
no  
me  
the  
the  
  
an  
Pl  
ma  
  
of  
for



A GUIDE  
TO  
OPERATIONS ON THE BRAIN

---

A.—INTRODUCTORY

THIS book is the first portion of a work upon which I have been engaged for the last six years; the time has mainly been spent in perfecting the method of illustration. There are few morphological anatomists who will not admit that the proper illustration of their work is one of the most important portions of their business, and that photography when properly directed—which has done so much for other sciences—is the only means by which this can be accomplished. The expense of reproduction is as yet the great drawback to its more general adoption, especially in the case of those who, like myself, have but limited resources; but the recent advances in photo-mechanical methods are of such promise that the worker may live in hope that the reproduction of his negatives will soon cost as little as that of crude and unsatisfactory line drawings.

The Plates, which form the principal part of this book and its most striking feature, afford but slight evidence of the large number which I have made, and which still await reproduction.

A year has elapsed since I exhibited the majority of them at Leeds and Newcastle, but the book has not suffered from the delay. Many of the Plates do not reach the degree of excellence which would satisfy me: and had I to do the work again, it would be better done. Of course these remarks do not apply to their reproduction, which has been done as well as possible by the Autotype Company. Any defect in the Plates is due to me in the making of the negatives.

The Text which accompanies the Plates may be considered as superfluous. The anatomy is objective, and can be read by anyone who may use this book. It might have been better had I supplemented each Plate with a lithographic key, in order to prevent possible mistakes. Nevertheless I trust the book may be found useful by those best qualified to judge.

I have to thank my friend Professor HARTLEY for kindly looking over the proof-sheets, and the Council of the College of Surgeons for building me a dark room. I am also indebted to the Messrs. CHURCHILL for the manner in which the book has been issued.



## B.—PERSONAL WORK

### I.—METHODS

#### 1. PREPARATION OF THE HEADS

The bodies, as soon as possible after death, are injected from the heart with an alcoholic solution of corrosive sublimate prepared as follows:—

Corrosive sublimate . . . . .	80 grammes
Methylated alcohol . . . . .	4 litres
Nitric or hydrochloric acid . . . . .	25 cubic centimetres

After the lapse of twenty-four hours another litre of the fluid may be injected, after which the injection is complete. To obtain the best results, it is necessary that the injection be made from the heart. I have prepared the heads, after their removal from the trunk, by injecting from the carotids and vertebrals; I have also—for the purpose of saving the thoracic cavity—injected the body from the femoral artery; but by both methods I have lost every head so prepared. The first series of heads was prepared with a solution of chloride of zinc, but in my hands the solution always caused too great a contraction of the brain, so that they had to be rejected.

After the second injection of the sublimate solution, the head and neck can be removed from the trunk by making an anterior skin incision from shoulder to shoulder, curving downwards over the chest-wall, several inches below the interclavicular notch, turning the skin upwards, sawing the manubrium between the first and second ribs, and the two clavicles at their acromial ends; then with the knife cut through the soft parts along the curve of the first intercostal space, separating the large vessels from the arch of the aorta, dividing also the trachea and the œsophagus, and sawing through the bodies of the second or third dorsal vertebra; then finally divide the remaining soft parts, taking away as much skin behind as will, along with the anterior flap, cover in the cut surface.

The head after removal is placed in spirit for eight or ten days—the spirit being changed from time to time, when the hardening will be complete externally.

The head is then shaved, and the anterior and posterior flaps of skin neatly stitched over the cut surface, when it is ready for embedding; but, as this is done with reference to the tapes, I shall here describe the manner in which these are placed on the cranial vault.

#### 2. FIXING THE TAPES

The tapes were hand-made, and divided into inches and half-inches. I am conscious of the drawback which the adoption of these measurements entails, but it is not insuperable, as they can readily enough be turned into centimetres.

The primary tape, with which all the others are connected, is the circumferential, passing horizontally round the vault of the head, from the root of the nose, between the eyebrows in front (glabella), to the maximum occipital point behind (should there be any difficulty in locating this latter point, take it as one inch above the external occipital protuberance), and thence round to the starting-point.

This tape, giving the circumferential measurement of the head, is then divided into four equal parts; if it is, say, 23 inches, then the subdivisions will be marked at  $5\frac{3}{4}$ ,  $11\frac{1}{2}$ , and  $17\frac{1}{4}$  inches; the starting-point and the  $11\frac{1}{2}$  inches are to be the poles where all the tapes running longitudinally are to meet; while the  $5\frac{3}{4}$  and the  $17\frac{1}{4}$  inches are to be the meeting-points of the tapes running transversely.

Practically I place these on the heads as follows. I do not start with running a tack through the beginning of the first inch of the circumferential tape alone, but, in addition, through all those that are to run in a longitudinal direction—that is, three if I am making the series of dissections from the top, the back, or the front of the head and neck, or two if I am working from



the side. I drive this tack, with these three or four tapes on it, through the scalp into the frontal bone at the point previously mentioned; then I run the circumferential tape laterally round the vault, passing over the posterior fixed point as also previously mentioned, and secure this tape by driving a second tack through it into the frontal bone at the starting-point; then I take the other three (or two) tapes and run one of them along the median longitudinal line of the head from front to back, and the remaining two (or one) laterally, so as to divide each lateral half of the median transverse tape into two equal parts, the three (or two) longitudinal tapes being finally fixed by driving a tack through them, and the centre of the circumferential tape into the scalp and the occipital bone behind.

I now proceed to place the transversely directed tapes, the median one running in a plane vertical to the circumferential tape, and passing through the ends of the first and third quadrants of this tape; this generally passes over the median longitudinal tape slightly in front of its centre, the posterior segment of the head being nearly always larger than the anterior.

I fix this tape by running a tack through it, and the median longitudinal into the bone where the two cross. I then divide the anterior and posterior segments of the vault mapped out by this median transverse tape and the circumferential into equal parts along the median longitudinal tape; and at these points I fix the anterior and posterior transverse tapes by running a tack through them and the median longitudinal one into the bone; the measurements on these three transverse tapes run (from their fixed points on the median longitudinal tape) from the beginning of the first inch on either side downwards towards the circumferential tape. The free ends of these three transversely directed tapes are then secured by passing a tack through them at the termination of the first and third quadrants of the circumferential tape, and the fixing of the tapes is complete.

A glance at Plates 1, 28, 33, 35, and 42 will enable the reader to understand how these lie better than any description of mine.

By means of the longitudinal tapes the vault above the circumferential one is divided into four segments, which are again subdivided by the transversely directed ones into a series of four right and left median spaces, and into a right and left lateral series of four. These I shall always speak of, passing from the frontal to the occipital end of the head, as the first, second, third, and fourth median spaces right or left, and the first, second, third, and fourth lateral spaces also right or left.

I shall also always speak of the tapes as the circumferential, the median, and the right and left lateral longitudinal, the median, and the anterior and posterior transverse, it being understood that the planes of the right and left lateral longitudinal, and those of the anterior and posterior transverse have an oblique as well as a longitudinal and transverse direction.

Preparatory to embedding, a rough set of these tapes are to be placed on the head.

### 3. EMBEDDING IN PLASTER OF PARIS

For this purpose five or six boxes are required, two feet long, eighteen inches wide, and seven inches deep. The head is placed in one of these, and embedded in the plaster up to the level of the tape corresponding to the series to be made. If this be the side series, up to the median longitudinal; if the top series, up to the circumferential one; if the front or back series, up to the median transverse; if the side oblique series, up to the right lateral longitudinal; and if it be the posterior top oblique series, up to the anterior transverse tape. The lower half of the preparation, before being placed in the box, is to be lubricated with oil; the plaster is then poured in roughly up to the levels before mentioned and allowed to set. The head is then removed, washed, and replaced in spirit. After an interval, which may vary according to convenience, the head is again replaced in its rough mould and accurately embedded. This can be repeated several times, until finally the head and its mould fit so accurately that it can be removed and replaced at will, without the slightest change in its position occurring during the progress of the serial dissections. After the accurate embedding is accomplished, the surface of the plaster inside the box, external to the preparation, is planed and levelled as far as the lower border of the tape; this surface is then blackened by several applications of a solution of lamp-black in turpentine. A new set of tapes is accurately adjusted on the vault of the head, and the box and preparation in it are then ready for the copying apparatus.



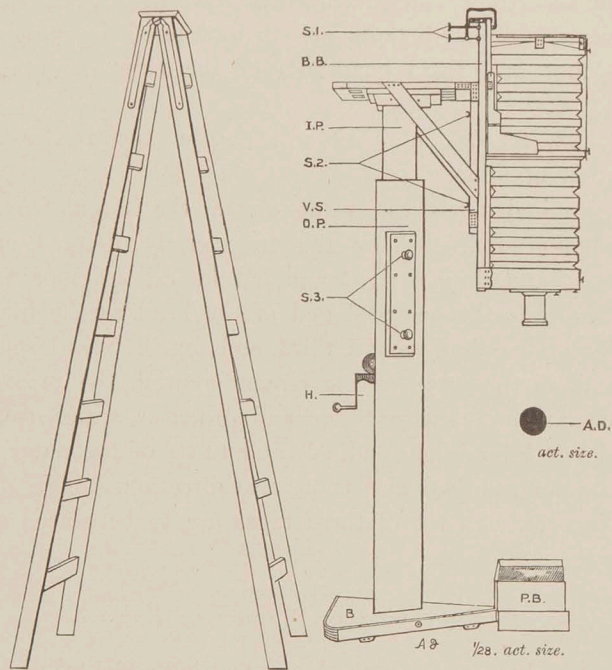
## 4. DESCRIPTION OF APPARATUS FOR SERIAL AND COMPOSITE PHOTOGRAPHY

It is well known to those familiar with recent embryological methods that embryologists, from their series of sagittal or coronal sections, can readily build up the entire internal structure of an embryo; and it was this method of embryonic reconstruction that guided me in the endeavour to apply it to the adult. I knew that if I could reproduce each serial dissection one after the other, natural size, then by making the prints taken from the negatives transparent, and placing them in order one over the other, I could read the entire structure at a glance.

At first I made the entire series from every point of view without placing tapes upon the head, forgetting that I could not project the vault on a plane surface without loss of roundness, so that although very pretty pictures were obtained they had little practical value. In beginning the work again and subjecting the tapes placed on the head to the same conditions as regards reproduction, the deeper-lying structures could be located on the scalp, with perfect practical accuracy.

How I conceived the idea of combining the superficial and deeper views I shall detail farther on. Thus it was by a very gradual and expensive process that I was able to master all the details of which the reproductions afford evidence.

I here reproduce a cut from a photograph of my apparatus, one-twenty-eighth actual size.



*Explanation of Fig. 1.*—B., base on which o.p., outer pillar, rises; I.P., inner pillar; v.s., vertical support for the camera; H., handle on outer pillar; B.B., base-board of camera; s.1, s.2, s.3, screws, uses of which are detailed in the text; P.B., box in which the preparation lies; A.D., diaphragm aperture, actual size. The ladder used for placing and removing the plates is shown at one side of the apparatus.

It was made after my own design and drawings by Mr. Meagher, of Southampton Row; and is so arranged that the camera is vertical. The supports for the camera consist of a base marked B., on which rises an outer hollow wooden pillar, seven feet in height, marked o.p., into which an inner wooden pillar fits, I.P., having a vertical movement of 3 feet 6 inches above the top of the outer pillar; this is worked by rack and pinion from the handle H., on the outer pillar. After raising or lowering the inner pillar it can be fixed by tightening the screws, s. 3, on the outer pillar.

The inner pillar supports the vertical wooden upright to which the base-board of the camera B.B. is attached by the screws s. 2. The screws s. 1, are for attaching the upper portion of the camera to its base-board. The camera can thus be raised to a height of  $10\frac{1}{2}$  feet, if necessary. Attached to the camera is a rapid rectilinear lens of 24-inch equivalent focus, made specially by Mr. Dallmeyer; the camera to suit this being made with a draw of 4 feet 6 inches, and to take plates  $15 \times 12$ .



All that is necessary to reproduce natural size with a lens of the above-mentioned focus is that its optical centre should be four feet from the preparation, and the same distance from the ground-glass screen of the camera.

The preparation, and the box in which it lies, are now placed under the apparatus in such a way that the centre of the preparation falls on the centre of the ground-glass screen; the box is then carefully levelled with the latter; the length or breadth of the head (according to the particular series being worked) is then taken with the calipers, and the image on the ground glass carefully adjusted to the same size by raising or lowering the camera from the handle on the outer pillar; this is then secured by tightening the screws s. 3. Final focussing is accomplished by the camera screw with a No. 3 Waterhouse diaphragm in the lens, in all cases directed to the most superficial portion of the tapes. When this is secured, the diaphragm is removed from the lens and a special one inserted, the actual size of the aperture of which I reproduce in Fig. 1, A. D. It is by means of this diaphragm that one is enabled to work through the entire head, step after step, without any further interference with the apparatus save that of removing and replacing the backs with the plates, each serial dissection being of natural size, and as sharp as the one for which the focus was made; although, of course, it lengthens the exposure very much. The preparation box, P. B., must never be moved after it has been placed in its position.

When I first began to make serial dissections it was essential for me to know whether the head always occupied the same position when it was replaced in its mould. In order to make sure of this I laid aside a double back with two plates, exposing each of them for the skin view, then again each of them for three or four different serial views, such as the external or median surface of the brain, for as many dissections as I thought would be a sufficient test for determining the object mentioned above, giving to each view a fourth or fifth of the exposure necessary for the making of a single serial negative. I was highly pleased to find, not only that the heads after their return to their mould always occupied the same position, but also that I had here a fertile means of showing the relations of the deeper parts to the skin surface.

Experience soon taught me the number of different views the plate would stand: whenever the light could be depended on the essentials of three could be shown, as in Plate 28, Fig. 1, and Plate 31, Fig. 1; but, for greater freedom in working, I am content to represent what I want of the skin (the tapes), and any additional deeper view of which I wish to show the relations to the scalp surface. In this manner the great majority of my illustrations have been made from Plates 11 to 42.

I was well acquainted with Mr. Galton's efforts in composite portraiture ('Inquiries into Human Faculty'), and also with those of American observers, recording the differences between various skulls (article 'Cephalometry,' in Vol. II. of Buck's 'Reference Handbook of the Medical Sciences'); but as these were practically the same objects which were passed in front of the sensitive plate, one face succeeding another, or one skull succeeding another, it never struck me that one plate could be made to depict views so different as the skin and the brain.

My experience being thus made plain, will elucidate the various steps to be taken before the skin view is disposed of, as the preparations for making the composite negatives have all to be undertaken before a knife can be placed in the head.

For obtaining composite negatives seven plates have to be exposed for the skin—one in a single back for the ordinary skin serial view, and the other six in three double backs, that being the number of composite negatives I make in working through each head. While the six plates are being placed in their double backs (in the dark room, of course) care has to be taken that they are fixed in such a manner as to make the slightest movement impossible while shifting or carrying the backs after the skin exposure; there being always a little play between the plates and the rebate of the slide,—I wedge them with a piece of wood. The necessity for this care is soon apparent, as, the head being always fixed, the shifting of the plate inside the back, after the skin exposure has been made, may cause a displacement of the relations of the deeper parts to the skin to the extent of an eighth of an inch. Having thus secured the six plates in their double backs, they are ready for use. The plate in the single back is, however, the first to be exposed. The time necessary for this with the diaphragm aperture figured in the cut varies from forty to eighty minutes, according to the quality of the



light, using plates of medium rapidity. The exposure for all the serial views after that of the skin is about twenty minutes longer, there being so many shadows to expose for in the dissections. The skin negative being developed and found in every way correct, the tapes running straight and requiring no touching up, the plates in the double backs, numbered from one to six, are exposed in succession for the skin. The exposure necessary varies from five to twenty minutes, according to the quality of the light, and has to be judged of solely from one's experience. The success of these composite negatives depends on the timing mainly of the skin view, all that is essential being the tapes, so that great care has to be exercised in judging of the actinic value of the light when the exposures are being made, as over or under exposure in the case of the skin are both alike fatal to the success of the final result. Moreover, as some of these plates have to lie in the dark room for over a week before the serial dissection can be reached for which they are again to be exposed, a slight difference of skin exposure has to be made in favour of those to be earliest finished, such as the skin and bone or skin and dura, these two being finished perhaps on the day succeeding that on which the skin exposure was made. All these details essential to success can only be learned after an experience that I, at least, have had to pay well for. The small amount of proportional exposure for the skin view is strengthened by the amount of time elapsing between the first and second exposures. The continuing action of the light on the film can be easily shown by developing a skin view at once after an eight minutes' exposure, and leaving another with the same amount of exposure for a week or more before development. At the end of this time it will be found to develop almost like a negative that had received the normal amount of exposure. I place here, from my note-book, the composite negatives from two heads as an example of the manner in which they have been made in the great majority of the heads enumerated in the table:—

## COMBINATIONS

*Female Child of four months, Profile Series, No. 11.*

1. { Skin	{ 7½ Minutes	{ Tuesday, April 22, 1889
{ Brain	{ 15 "	{ Friday, " 25, "
2. { Skin	{ 6 "	{ Tuesday, " 22, "
{ Brain	{ 17 "	{ Friday, " 25, "
3. { Skin	{ 6 "	{ Tuesday, " 22, "
{ Central Lobes	{ 15 "	{ Saturday, " 26, "
4. { Skin	{ 6 "	{ Tuesday, " 22, "
{ Median Surface	{ 20 "	{ Saturday, " 26, "
5. { Skin	{ 9 "	{ Tuesday, " 22, "
{ Bone	{ 20 "	{ Wednesday, 23, "
6. { Skin	{ 8 "	{ Tuesday, " 22, "
{ Dura	{ 17 "	{ Thursday, " 24, "

*Male Adult, Profile Series, No. 8.*

1. { Skin	{ 10 Minutes	{ Wednesday, February 19, 1890	} ruined
{ —	{ —	{ —	
2. { Skin	{ 12 "	{ Thursday, " 20, "	
{ Bone	{ 40 "	{ " " " " " "	
3. { Skin	{ 10 "	{ Wednesday, " 19, "	
{ Brain	{ 45 "	{ Saturday, " 22, "	
4. { Skin	{ 9 "	{ Wednesday, " 19, "	
{ Central Lobes	{ 40 "	{ Monday, " 24, "	
5. { Skin	{ 15 "	{ Wednesday, " 19, "	
{ Dura	{ 60 "	{ Friday, " 21, "	
6. { Skin	{ 15 "	{ Wednesday, " 19, "	
{ Median Surface	{ 45 "	{ " " " 26, "	

These composite negatives could be made, I dare say, with less trouble from the corresponding serial negatives; but the proper registration and the timing for the different views would entail a considerable amount of work.

The serial photographs, then, as in Plates 1 to 10, all of natural size, are made by means of the small aperture of the diaphragm in the lens, while the composite negatives are made in the manner that has been detailed.



II.—TABLES SHOWING THE NUMBER OF ADULT AND YOUNG HEADS DISSECTED SERIALLY, WITH THE NUMBER OF NEGATIVES MADE OF EACH HEAD, AND ALSO OTHER PARTICULARS

TABLE A.—Profile Series														
—	No.	Measurements in Inches									Sex	Age in Years	Results as regards Preparation	Number of Negatives Serial and Composite
		Circumferential	Median Longitudinal	Left Lateral Longitudinal	Median Transverse (half)	Anterior Transverse (half)	Posterior Transverse (half)	Length	Breadth	Cephalic Index				
Adult	1	—	—	—	—	—	—	—	—	—	Male	40	Very good	14
	2	—	—	—	—	—	—	—	—	—	Male	45	Bad	15
	3	23½	13	12¾	5½	5½	6½	8	6¼	78	Male	46	Excellent	25
	4	21¾	12½	12	5½	5½	5¾	7½	5¾	77	Female Lunatic	38	Excellent	22
	5	20⅝	12	11½	5⅝	5¼	5½	7½	—	—	Male	45	Very good	16
	6	21¼	11¾	11½	5⅝	5⅝	5¾	7½	5½	72	Male	50	Very good	18
	7	21½	12½	12	5¾	5¾	6	7¾	5¾	74	Male	55	Bad	12
	8	23	12⅝	12½	5¾	5¾	6¼	8	6½	76.5	Male	45	Excellent	18
	9	20¼	12	11½	5¾	5⅝	5⅝	—	—	—	Female	15	Very good	17
	10	16	9	8⅝	4¼	4¼	4¼	—	—	—	Female	22 months	Excellent	24
Children	11	14¼	8⅝	8	3¾	3⅝	4	—	—	Female	4 months	Very good	34	
Adult Oblique	12	21¼	12½	11¾	5½	5½	5⅝	7½	5⅝	74	Male	50	Excellent	16
Total													231	

TABLE B.—Vertical Series														
Adult	1	—	—	—	—	—	—	—	—	—	Male	50	Excellent	14
	2	23½	11¾	11½	5¼	5⅝	6	8⅝	6⅝	76	Male	45	Bad	8
	3	23½	11¾	11½	5¼	5¾	5⅝	7¾	6	77.5	Male	65	Bad	5
	4	21½	12¼	12	5⅝	5½	5⅝	7¾	5½	71	Female	28	Excellent	10
	5	22⅞	12¾	12¼	5¾	5½	6	8¼	6¼	78	Male	50	Excellent	18
	6	20½	11⅝	11½	5¼	5¼	5½	7½	5¾	77	Female	30	Excellent	20
	7	22½	12⅞	12⅝	6	5¾	6½	8¼	6½	79	Male	40	Excellent	16
	8	16¾	9½	9¼	4⅝	4¼	4½	5⅝	4½	77	Female	15 months	Excellent	14
Children	9	16½	10	9⅝	4½	4½	4⅝	6	4¾	79	Male	19 months	Excellent	20
Adult Oblique	10	21	11⅝	11⅝	5½	—	5½	7⅝	5⅝	74	Male	25	Very good	16
11	21	12½	11⅝	5¾	—	6⅝	—	—	—	Male	30	Excellent	14	
Total													155	

TABLE C.—Occipital Series														
Adult	1	—	—	—	—	—	—	—	—	—	Male	—	Very good	18
	2	—	—	—	—	—	—	—	—	—	Male	—	Very good	12
	3	21¾	12½	11⅝	5½	—	6	7½	6	80	Male	45	Bad	8
	4	21⅝	12¼	11¾	5¼	—	5⅝	7¾	5¾	74	Male	50	Very good	24
	5	20⅝	12⅝	11¾	5½	—	5¾	7¼	5¾	79	Female	40	Excellent	21
	6	21¾	11¾	11⅝	5⅝	—	5¾	7⅝	5⅝	71	Male	45	Excellent	14
	7	22	12½	12	5½	—	6	8	6	75	Male	55	Excellent	20
Children	8	15	8½	8¼	3⅝	—	4	5¼	4⅝	78.5	Male	5 months	Bad	14
	9	16	9½	9¼	4¼	—	4½	—	—	—	Female	14	Excellent	38

TABLE D.—Frontal Series														
Adult	1	—	—	—	—	—	—	—	—	—	Male	40	Excellent	14
	2	21¼	—	—	—	—	—	—	—	—	Female	30	Excellent	17
Total													200	



III.—DESCRIPTION OF THE SERIAL DISSECTIONS SO FAR AS THEY  
HAVE BEEN REPRODUCED

I have not been able to do justice to these from the six points of view from which they have been made, that is, from the side, obliquely from the side, the top, obliquely from the top, the back, and from the front.

I have only been able to reproduce fourteen of the negatives—Plates 1 to 10, 29, Fig. 2, 32, Fig. 2, 34 and 36, out of a total of more than four hundred serial negatives.

The dissections from every one of these points of view follow a natural order: thus the skin view, the dissections of the bone, the dura, the pia, the external surface of the brain, the central lobes and lateral ventricles, are common to all, the further dissections being made to suit the particular point of view from which one is working until the whole of the anatomy of the contents of the cranial and cervical spinal cavities has been reproduced. I have made as many as sixteen different views in travelling from side to side of the head, or from back to front, or front to back, and twelve in working from the vertex to the base of the skull.

For every one of these views the head has to be removed from its mould, dissected under spirit, then replaced; and the serial negative made for every separate view, and the composites exposed on the bone, the dura, the pia, the external surface of the brain, the central lobes and lateral ventricle, and, lastly, the median surface of the brain if one is working from the side, when these particular dissections have been reached.

During the progress of the dissections, the soft parts are frequently found stained red from escaped blood-colouring matter; the dissection can be readily bleached by the application of the injecting fluid wrung from a sponge. This bleaching is a point of some importance, as it adds greatly to the beauty of the preparations, and to the ease of their reproduction on the sensitive plate, that they should be as white as possible. With these remarks in regard to the working of the dissections generally, I pass to their description, and first as to the

*Skin* (Plate 1).—As far as this view is concerned there is nothing of much moment after the tapes have been properly fixed, except the great difference that exists in the various heads in respect to the pinna. This varies much in size, and considerably in position, so that any results based on lines drawn from any part of it are not applicable generally, nor of much value from a practical or any other point of view. It is very large in Plate 1, while the outlines of it seen in the composite Plates 11, 12, 14, 16, 17, 22, and 23 illustrate the manner in which it differs in the various heads.

*The Bone* (Plate 2).—This dissection shows the left lateral half of the cranial, the facial, and the cervical vertebral skeleton, and the cranial sutures, and is made by incising the skin along the median longitudinal plane of the head and neck, removing the scalp from the cranial vault, with the periosteum and all the overlying structures from the facial bones, and the contents of the orbital cavity, then all the soft parts from the cervical part of the vertebral column, carefully dissecting out the vertebral artery on the arch of the atlas, and the anterior and posterior branches of the first, second, third, and fourth cervical nerves, as well as the anterior branches of the remaining cervical and upper dorsal nerves, the internal jugular vein, the common carotid artery and its two principal divisions, the cranial nerves behind the seventh; then the muscles covering the thyroid gland, the cricoid and thyroid cartilages, and passing to the hyoid bone, are to be removed. The dissection is finally finished by removing the pterygoid muscles underneath the inferior maxillary bone, leaving the third division of the fifth nerve and the middle meningeal artery. Plate 33 shows the bone dissection from the back in a child, where not only the greater part of the vertebral column but also all the ribs are shown.

*The Dura* (Plate 3).—This dissection is made by sawing through the calvarium in the mid-sagittal line from the root of the nose to the foramen magnum, then horizontally from the upper margin of the orbit to the external occipital protuberance, and removing this portion of the bony vault; the saw is then passed through the malar bone external to the outer margin of the orbital cavity and through the mandible at the symphysis, the zygomatic arch is divided at its root, and the left half of the mandible with the arch is removed by dividing the soft parts from the side of the tongue;



opening up the cavity of the pharynx, thus laying bare the tongue and portions of the genio-hyoid and genio-hyo-glossi muscles.

The vertebral canal is then exposed by removing those portions of the vertebral arches between the middle line behind and the intervertebral foramina in front, leaving the transverse processes with the nerves resting on them, carefully dissecting out the vertebral artery in all its length.

To complete the dissection and lay bare the entire left lateral surface of the cranial dura, the greater part of the corresponding half of the occipital bone, all the temporal external to the membrana-tympani (exposing the auditory ossicles at the same time), the great wing of the sphenoid external to the pterygoid plate—opening the foramen ovale and foramen spinosum, thus exposing the middle meningeal artery and the third division of the fifth nerve—and the remaining portions of the frontal bone above the upper margin of the orbital cavity, have all to be removed with the bone-forceps; and finally the lateral and superior longitudinal sinuses are to be opened up. On the surface of the dura is seen the course and distribution of the middle meningeal artery, which, after entering the skull cavity at the foramen spinosum, divides into two large branches—first, the vertical, which curves towards the front, ascending a little behind the anterior margin of the temporo-sphenoidal lobe, passing upwards parallel to but slightly behind the coronal suture towards the middle line of the head. At the level of the sylvian fissure it gives off subsidiary branches, one of which passes forwards and supplies the anterior frontal part of the dura; the others pass backwards and supply the dura over the hinder part of the frontal, and the anterior portion of the parietal lobes. The second more or less horizontal branch of the artery passes backwards, giving off secondary branches, which supply the dura over the lower temporo-sphenoidal, the posterior parietal, and in part the occipital regions. The entire course of the lateral sinus with the venous openings in it is shown, as well as the dura over the cerebellum and the cord.

*The Pia Arachnoid* (Plate 4).—This view is laid bare by cutting the dura along the lateral border of the superior longitudinal sinus from front to back, the incision being continued along the upper border of the lateral sinus, and laterally along the line of the previous bone-dissection to the middle line in front where the incision was begun, and removing this portion of the dura. Another incision is then made through the dura, at the lower border of the lateral sinus, running from the jugular foramen to the internal occipital protuberance; and below this point along the median cut surface of the occipital bone, and the vertebral arches in the middle line behind. This portion of the cranial and spinal dura is removed by incising it laterally along the exit of the upper dorsal, all the cervical, and posterior cranial nerve roots until the jugular foramen is again reached, where the incision was begun. That portion of the vertebral artery resting on the arch of the atlas, with the external and common carotid arteries, the jugular vein, and the transverse processes of the vertebræ are removed, and the view is complete. It shows the vessels on the external surface of the cerebrum and cerebellum; the veins on the former run so as to enter the superior longitudinal or the lateral sinus. The principal one lies in the horizontal limb of the sylvian fissure, at the hinder part of which it divides into two, one of the divisions passing upwards over the parietal lobe to the superior sinus, while the other passes down over the posterior part of the temporo-sphenoidal lobe to the preoccipital notch where it enters the lateral sinus. This latter is more evident in other series than in Plate 4.

*External Surface of the Brain* (Plates 5 and 6, from the side; Plate 32, Fig. 2, posterior three-fourths from the top; Plate 34 from the back).—For the side views, the pia-arachnoid, the petrous part of the temporal bone as far as the internal auditory meatus, the lateral sinus, portions of the basi-sphenoid and basi-occipital bones (to expose the contents of the jugular fossa) have all been removed. The carotid canal and the Eustachian tube have been opened up. The walls of the orbital cavity, except the inner and part of the lower, have been removed to show the orbital surface of the frontal lobe and the cranial nerves entering the orbital cavity; also sufficient of the superior maxillary bone to expose the inner wall of the antrum of Highmore.

The tongue, soft palate, epiglottis, larynx, trachea, and œsophagus have been divided along the middle line (or near it), the posterior cranial and cervical spinal nerves with the internal carotid artery have been cut short, and the dissection is then complete. In Plate 5 the lower part of the



neck has been embedded too far towards the front, the natural curve of the spinal cord being thus lost, as shown in Plates 6, 14, 16, and 17. The dissection in Plate 6 differs slightly from that in Plate 5; thus part of the roof of the orbit is left; the tongue is not divided, the cavity of the pharynx is not opened up completely, and the cranial nerves are not so well shown. In the corresponding dissections of the children's heads the chief difference is the marked concave form of the orbital surface of the frontal lobe, due to the convex form of the upper wall of the orbital cavity.

As those for whom this work is intended know the anatomy of the central nervous system, I require only to indicate the manner in which I have marked the well-known divisions of the convexity of the brain. I have followed the widely-accepted description of Ecker ('Convolutions of the Human Brain,' 2nd edition) with certain minor additions, such as the annectant convolutions of Gratiolet, and may state here generally that there is no difficulty in accepting his description for those parts of the convexity in front of the posterior central convolution or for the external surface of the temporo-sphenoidal lobe. The difficulty occurs when one endeavours to make a single description applicable to the connections of the supramarginal and angular gyri of the parietal lobe, with the superior parietal lobule on the one hand and the superior and middle temporo-sphenoidal convolutions on the other. The variations in regard to these are so frequent that no two of my specimens are exactly similar: the supramarginal and angular gyri may be so closely connected with the superior parietal lobule as to give rise to three well-marked post-central convolutions (Plate 32, Fig. 2), and to two, or even three, post-rolandic sulci; or the supramarginal gyrus may be so apparently separate from the angular and the superior parietal that the parallel sulcus is continuous with the lower half of the vertical ramus of the intraparietal sulcus (Plate 27, Fig. 1). Again, there is difficulty in adopting a single description for what is to be the natural or artificial boundaries which separate the occipital from the parietal and temporo-sphenoidal lobes.

It is in regard to the difficulties of these particular regions that, in my experience, I have found the descriptions of Wernicke ('Archiv für Psychiatrie,' Bd. vi., Heft 1, page 298, and Bd. 1 of his 'Lehrbuch der Gehirnkrankeiten') and Meynert (Part 1 of his 'Psychiatry') nearer the truth than that of Ecker. It is impossible that the end of the parallel sulcus can be where the latter represents it in his well-known diagram from the side, so frequently copied. In regard to the separation of the occipital from the parietal and temporo-sphenoidal lobes, Wernicke describes an anterior occipital sulcus, found always behind the ascending limb of the middle temporo-sphenoidal convolution, Plates 6, 14, 16, and 19. This ascending limb lies posterior to the upper end of the parallel sulcus, and may, apparently, spring at times from the superior temporo-sphenoidal convolution, Plates 5 and 16. Meynert calls this sulcus the external occipital fissure, it being homologous to the well-developed fissure in the lower apes. Wernicke also recognises another sulcus, which he calls the inferior occipital, separating the occipital from the temporo-sphenoidal lobe. This is the same as Meynert's preoccipital sulcus, or Schwalbe's preoccipital notch. It is found frequently among the apes, and may be continuous with the fusiform or inferior temporal sulcus. Noting these differences, Ecker's description has been mainly followed. I have marked the divisions on the external surface with Arabic numerals, but the median surface, being so well known, I have left unmarked; in one child's head also the external surface is unmarked, Plate 18. I have used the figures 1, 2, 3, for the upper, middle, and lower frontal convolutions; 4, for the precentral or ascending frontal; and 5, for the orbital convolutions of this lobe. 1 has been used for the post-central or ascending parietal; 2, for the superior parietal lobule; 3, for the supramarginal; and 4, for the angular gyrus of the parietal lobe. (In Plate 6 the figure 4 is placed slightly too far back.) The figures 1, 2, 3, and 4 have been placed on the four annectant convolutions, if they are all present; 1 on the first just external to the parieto-occipital fissure, while the remaining figures are placed on the corresponding convolutions, in a line between this fissure and the preoccipital notch. The figures 1, 2, 3 are placed on the upper, middle, and lower occipital convolutions; and also on the upper, middle, and lower temporo-sphenoidal. The figures have been placed on any part of these subdivisions of the various lobes. In Plate 6, the letters A, B, C, and D are placed on the frontal, parietal, occipital, and temporo-sphenoidal lobes respectively, but only on this head — one of my earliest. In addition, in nearly all the heads illustrated, I have used the figure 1 to mark the extremities of the horizontal limb



of the sylvian fissure, figure 2 for the median and lateral extremities of the central sulcus, and figure 3 for marking the external parieto-occipital fissure.

In addition to the cerebral external surface in this view are seen portions of the upper and lower surfaces of the left hemisphere of the cerebellum, and the Figures 1, 2, and 3 (in Plate 6) are placed on the posterior inferior, the slender, and the biventral lobes of its under surface, while the postero-superior and part of the quadrate lobe can be seen above the great horizontal fissure. A part of the flocculus, as well as the anterior and posterior cervical and upper dorsal nerve roots, are also displayed. The connection of the spinal-accessory with the first cervical nerve is noteworthy. Although the posterior roots of the latter nerve are generally absent, yet I have seen it, both in the child and in the adult, with as many as three bundles of fibres, forming posterior roots similar to the succeeding spinal nerves. Plate 34 shows the dissection of the brain from the back, and the manner in which the cord with the cervical and upper dorsal nerves have been laid bare.

The view from the top can be judged of from the skin and brain composites, and also the posterior three-fourths of the brain in Plate 32, Fig. 2.

*Central Lobes and Lateral Ventricle* (Plate 7). To expose these the brain is dissected as follows:

The posterior horn of the lateral ventricle is opened from the side. Then the knife is directed forwards, along the curve of the ventricular surface of the caudate nucleus, incising the corona radiata obliquely from the caudate nucleus, to the junction of the cortex of the central lobe with that of the operculum as far as the floor of the anterior horn of the ventricle, sweeping round from the anterior end of the island, when the incision is carried through the thickness of the frontal lobe, then along the curve of the hemisphere from front to back, about one inch external to its median border, laying bare the roof of the ventricle and its posterior horn. The coronal part of the incision is then prolonged downwards, the knife passing between the junction of the cortex of the island with the upper surface of the temporal lobe and the curved portion of the caudate nucleus in the roof of the descending horn of the ventricle, as far as the anterior end of the descending horn; the knife is then passed through the thickness of the anterior extremity of the temporo-sphenoidal lobe, the incision passing outwards and then prolonged backwards through this lobe and the occipital on a level with the floor of the descending and posterior horns until it meets the first incision at the occipital pole, thus leaving about an inch of the external surface of the temporal and occipital lobes above their lower borders. All that portion of the hemisphere isolated by the above incisions is then removed, and the central lobe and lateral ventricle are exposed.

To complete the dissection the nasal cavity is opened up by removing the wing of the nose, the nasal, ethmoid, superior maxillary, and part of the sphenoid bones, almost to the middle line. The hard and soft palates are divided, and the septum of the nose is laid bare. Portions of the petrous part of the temporal bone, the occipital, and the bodies of the cervical and upper dorsal vertebræ to near the middle line, are removed.

The vertebral artery has been taken away, and portions of the posterior cranial and the upper spinal nerves beyond the ganglia on their posterior roots have been removed, and the dissection is complete.

In this dissection the only parts of the corona radiata left uncut are those that run to the lower portions of the frontal and temporo-sphenoidal lobes, situated below the anterior horn and in front of the descending horn of the lateral ventricle, also in front and behind the anterior perforated space. These and the corpus callosum are all that prevents the entire mantle part of the hemisphere from being lifted off.

In the posterior horn of the ventricle are seen two swellings, the lower of which is the calcar avis, or hippocampus minor, the upper the forceps major of the corpus callosum as it passes towards the occipital lobe.

A point worthy of notice in the posterior horn of many ventricles is illustrated in Plate 7, where the horn is seen to be in two divisions; the septum which divides the cavity into two is in this instance fully one-fourth of an inch in thickness. I have on several occasions found two septa, dividing the cavity of the horn into three loculi. This condition would explain the discrepancies of many descriptions when the cavity of this horn has been said to be short or wanting; had search been made other loculi of the cavity would have been found, although separated from the general ventricular cavity by the septa noted above.



This view is a very instructive one, showing the gyri of the central lobe, almost the whole of the corona radiata, and the thickness of the hemisphere to be passed through before the cavity of the ventricle can be reached; the situation where this can be done most easily being along the course of the posterior horn.

To illustrate this I have reproduced the seventh serial dissection of one of the heads from the top, Plate 29, Fig. 2, which shows the thickness of the hemisphere between the cavity of the posterior horn and the bone, laterally behind the pinna. The cavity of the ventricle is nearer the skin surface here than at any other part, as can be judged by glancing along the course of the ventricular roof shown in Plate 7. I have also added the dissection of the ventricle from the back in Plate 36, and the measurements to reach it can be read from the tapes in Plate 38, which is a composite plate from the same series.

Another point of some anatomical importance is the curve shown along the superior and internal portion of the wall of the ventricular cavity just where this passes into the posterior horn. This curve in my experience corresponds to a portion of the floor of the intra-parietal sulcus, a sulcus of more importance than is generally supposed. It looks as if the curve were the corresponding eminence of this portion of the sulcus in the cavity of the ventricle; if so the sulcus would be raised to the importance of a primary fissure, similar to the calcarine, and of more significance than such a fissure as the collateral. The floor of a portion of the internal parieto-occipital fissure is very close to this curve also. If the presence of this curve on the roof of the ventricle does not depend on the forceps major of the corpus callosum, it may on the supposition stated briefly above.

*Falx Major and Cerebellum* (Plate 8).—For the preparation of this view the remaining part of the hemisphere is removed by cutting the frontal and temporal ends of the corona radiata, snipping through with the scissors the fornix and splenium of the corpus callosum, and prolonging the incision for the entire length of the latter, slightly external to the median line. The gyri of the central lobe are then removed by a longitudinal incision passing slightly external to the ventricular margin of the caudate nucleus, along its curve, and ending below at the anterior perforated spot; in this way laying bare the grey matter of the lenticular nucleus and the almost circular arrangement of the peduncular fibres as the corona passes downwards to become the internal capsule; the frontal and temporal ends of the corona being only separated by the grey matter of the anterior perforated space, the latter being continuous with that of the lenticular nucleus. The pia-arachnoid is then removed from the mid-brain and the upper surface of the cerebellum. The cranial nerves from the first to the twelfth are displayed in the greater part of their intracranial course, and finally the superior longitudinal, the straight, and inferior longitudinal sinuses are opened up, and the view is finished.

It displays, in addition to the parts already mentioned, the pulvinar of the optic thalamus, the lateral surface of the mid-brain, the pons, and the anterior cerebral artery.

*Pia-arachnoid of Median Surface* (Plate 9).—This and the succeeding plate are from the same head as Plate 6, and the view has been made by removing the falx cerebri and an additional portion of the central lobe, so as to expose the internal capsule, with the lenticular and part of the caudate nucleus of the corpus striatum. It shows clearly the manner in which the internal capsule is broken up by the bands of grey matter passing between the lenticular and caudate nuclei, as well as the continuity of the first-named nucleus with the grey anterior perforated space.

On the median surface the vessels of the pia mater are exposed, and the groove on the occipital end of the right hemisphere, caused by the superior longitudinal sinus. The cranial nerves, except the second, have been removed in the greater part of their extent. The cervical and upper dorsal have been thrown backwards to show their anterior roots. The bodies of the cervical vertebræ have been divided along the middle line, exposing the intervertebral discs; the median septum of the nose, the ethmoid, body of the sphenoid, and the basi-occipital have also been removed to the middle line. This lays bare the pituitary body, the basilar artery, the external wall of the nasal cavity with its four meatuses, and the opening of the Eustachian tube with the pharyngeal pouch behind it. The remaining portions of the dissection are similar to the preceding.

*The Median Surface* (Plate 10).—The pia-arachnoid, the anterior cerebral artery, and other vessels have been removed, to lay bare this surface of the hemisphere. The mid, hind, and after brain, with the spinal cord, are then divided along the middle line—as well as the corpus callosum, the fornix,



and walls of the inter-brain—and the parts removed, when the view is complete. On the median surface is seen, from behind forwards, part of the lingual lobule, the cuneus, the quadrate and paracentral lobules, the marginal and fornicate gyri, the latter divided in front and continuous behind with the quadrate lobule and the uncinata gyrus.

Separating these divisions are the well-known calcarine and parieto-occipital fissures, and the callosomarginal sulcus. Underneath the corpus callosum are the septum pellucidum and the fornix.

I need not mention the well-known structures seen on the median surfaces of the inter, mid, hind, and after brain. The pineal gland was by accident removed, although its peduncle, passing along the median surface of the thalamus opticus, is plainly seen; additional portions of the bodies of the vertebræ, the basi-occipital, and the pre- and post-sphenoid bones have been removed. The remaining portions of this view are similar to the preceding.

This finishes the slight description of the dissections which I have selected to illustrate the series from the side, although these go on, and should have been reproduced, until the inner surface of the bone in both the cranial and spinal cavities is reached. I have not been able to reproduce the serial negatives from the remaining points of view in which they have been made, except an occasional one or two. These can, however, be judged of in the composites for the several side series in Plates 11 to 27; for the several top series in Plates 28 to 32; for the several back series in Plates 33 to 41; and for the series from the front in Plate 42.

In the serial dissections of the children from the side and back, the anatomy of the contents of the thoracic and abdominal cavities, as well as those of the head and vertebral canal, have been reproduced.

#### IV.—DESCRIPTION OF THE RELATIONS OF THE DEEPER LYING STRUCTURES TO THE SURFACE OF THE SCALP

Before entering upon the most important part of this work, a few general remarks may be made: first, in regard to the tapes. The measurements on these all run from the beginning of the first inch from the starting-point at the root of the nose in the longitudinally-directed ones; on the transverse tapes, the beginning of the first inch is at their fixed points in the mid-sagittal line of the head, and the inches run from this on either side.

Another point is that to reach any deeper structure shown in its natural position to the measurements placed on the scalp surface, the knife of the operator must always be directed vertical to the plane of embedding of the particular series on which he is depending after planning his operation, whether that be from the side, the top, the back, or from the front. And, finally, that the key-note of all the remarks which are to follow is this: *that for normal heads after birth the position of any structure of importance in their cavities varies proportionally with the variations of the circumference as given by the circumferential tapes of the respective heads.*

I have no experience of artificially deformed heads, or of pathological ones, and therefore cannot speak of them. This rule may not be absolute, but it is the nearest approach to the truth which I have been able to find, or of which the nature of the subject permits, and for all practical purposes can be depended upon.

##### 1. RELATIONS OF THE CRANIAL SUTURES TO THE SCALP SURFACE (PLATES 11, 12, AND 33)

The circumference of the adult heads which I have worked over varied from  $20\frac{1}{4}$  to  $23\frac{1}{2}$  inches. The junction of the coronal with the sagittal suture in these heads varied from  $4\frac{7}{8}$  to  $5\frac{3}{4}$  inches from the root of the nose. Its lateral lower border (that is, where it joins the great wing of the sphenoid) was found on verticals from the circumferential tape, varying on the latter from  $3\frac{1}{4}$  to  $3\frac{3}{4}$  inches.

In children with circumferential measurements varying from  $14\frac{1}{4}$  to  $16\frac{3}{4}$  inches, it was found laterally on verticals from the circumferential tape, varying on the latter from  $2\frac{1}{4}$  to  $2\frac{5}{8}$  inches. The median measurements in these heads could not be determined in consequence of the presence of the anterior fontanelle. This suture occupies portions of the first and second lateral spaces, and the second median space to the extent shown in Plates 11 and 12. The junction of the



lambdoid with the sagittal suture in the adult varied from  $9\frac{3}{4}$  to  $11\frac{1}{8}$  inches, in children from  $7\frac{3}{8}$  to  $8\frac{1}{4}$  inches, Plate 33. Laterally this suture was found to vary on the circumferential tape at the point where it was crossed by the latter in the adult from  $7\frac{3}{4}$  to  $8\frac{3}{4}$  inches, and in children from  $5\frac{1}{2}$  to  $6\frac{1}{2}$  inches.

The sphenoido-squamous suture on the circumferential tape was found in the adult to vary from  $3\frac{1}{2}$  to  $4\frac{1}{8}$  inches, and in children from  $2\frac{1}{2}$  to  $2\frac{7}{8}$  inches. The upper border of the squamous suture in the adult varies on the median transverse tape from  $4\frac{3}{8}$  to 5 inches, and in the children from  $3\frac{3}{4}$  to  $4\frac{1}{8}$  inches. These variations, with one apparent exception, depend upon the variations in the circumference of the heads; thus, the variations of the junction of the coronal with the sagittal suture in the adult of  $4\frac{7}{8}$  to  $5\frac{3}{4}$  inches is proportional to the variations from  $20\frac{1}{4}$  to  $23\frac{1}{2}$  inches in the circumference of the heads.

It is the same in the children: thus, if the sphenoido-squamous suture on the circumferential tape falls at  $4\frac{1}{8}$  inches in the  $23\frac{1}{2}$ -inch adult head (Plate 17), then in the child with a circumference of  $14\frac{1}{4}$  inches it will fall at the  $2\frac{1}{2}$ -inch (Plate 19 and woodcut, Fig. 2). This practically

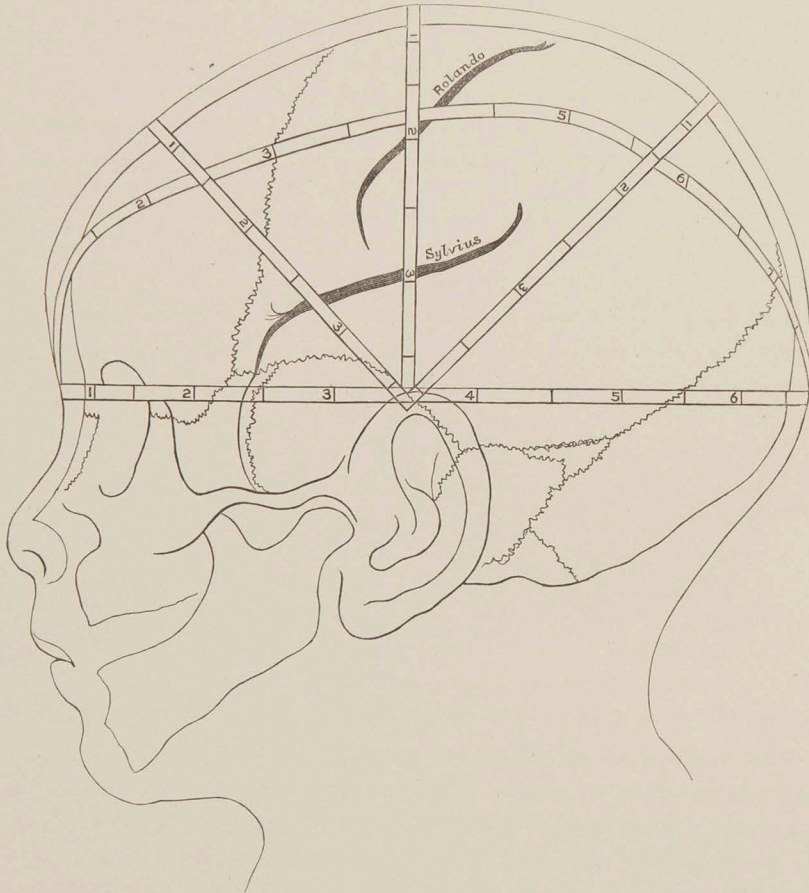


FIG. 2.—Head of female child of four months to show the relation of the squamous suture to the fissure of Sylvius, and of both to the tapes. Natural size.

holds good for all, with the apparent exception previously noted. That is the distance of the squamous suture from the middle line of the head in the child and in the adult, or rather, as has been frequently noted by different observers, the different relations which this suture bears in the child and in the adult to the sylvian fissure; it is well known that in the latter the anterior portion of the squamous suture corresponds to the anterior part of the horizontal limb of the fissure of Sylvius, while in the child it is apparently much lower down, opposite the middle temporo-sphenoidal convolution. Now observers have not noticed the fact that the two sutures are not comparable in the child and in the adult; in the former it is a linear suture, that is, there is no overlapping of the external surface of the parietal bone by the squamous part of the temporal in the child, whereas in the adult the parietal is overlapped by the squamous part of the temporal to the extent of nearly one inch.



It is the lower borders of the parietal bones in the child and in the adult (the portion of the squamous suture in the latter seen inside the head) that are the comparable parts; and these when measured from the middle line, will also be found to be in proportional positions to the circumference of the heads, and to occupy corresponding relations to the temporo-sphenoidal lobes. The composite negative of a child's head showing skin and bone and illustrating this was unfortunately broken in transit. I here substitute a woodcut (Fig. 2).

The upper border of this suture, then, externally is not of any value for purposes of comparison; it is the inner margin of the suture that has to be taken in the adult for this purpose. The amount of parietal bone overlapped between the outer and inner lips of the suture is subject to considerable variation, as can be seen by examining the squamous portion of a large number of different temporal bones.

The variations of these sutures may be tabulated as follows:—

Suture	Tape	Adult (20 $\frac{1}{4}$ to 23 $\frac{1}{2}$ circumf.)		Children (14 $\frac{1}{4}$ to 16 $\frac{3}{4}$ circumf.)	
Coronal	Median longitudinal	4 $\frac{3}{4}$	5 $\frac{3}{4}$	2 $\frac{1}{4}$	2 $\frac{3}{8}$
	Circumferential	3 $\frac{1}{4}$	3 $\frac{3}{4}$	—	—
Lambdoid	Median longitudinal	9 $\frac{3}{4}$	11 $\frac{1}{8}$	7 $\frac{3}{8}$	8 $\frac{1}{4}$
	Circumferential	7 $\frac{3}{4}$	8 $\frac{3}{4}$	5 $\frac{1}{2}$	6 $\frac{1}{2}$
Sphenoido-squamous	Circumferential	3 $\frac{1}{2}$	4 $\frac{1}{2}$	2 $\frac{1}{2}$	2 $\frac{7}{8}$
Squamous	Median transverse	4 $\frac{3}{8}$	5	3 $\frac{3}{4}$	4 $\frac{1}{4}$

## 2. RELATIONS OF THE DURA WITH ITS CHIEF ARTERY AND THE LATERAL SINUS TO THE SCALP (PLATE 13)

The anterior or vertical branch of the middle meningeal artery passes through the first and second lateral spaces into the second median one. The posterior or horizontal division passes beneath the meeting of the three transverse tapes into the third lateral and median spaces, giving off branches into the fourth lateral space also. The exact relation of these divisions to the tapes can be read by glancing at the plate, or by applying the compass to the branches of the artery shown in Plate 3 and reading off the measurements from the tapes in Plate 1. The position of the superior longitudinal sinus I need not refer to; while the course of the lateral sinus from the internal occipital protuberance behind to its termination as the jugular vein in front can be read at a glance; in its entire course it lies under the circumferential tape, the upper lateral margin approaching nearest to the tape between the 6 $\frac{1}{2}$  inches and 7 inches, then sloping downwards over the lateral border of the cerebellum, internal to the mastoid process, and finally ends at the jugular foramen.

Its lateral position can be judged of also from a large number of the succeeding Plates, and its posterior relations to the tape measurements can be seen in Plates 35 and 37, and its course in Plate 34.

## 3. RELATIONS OF THE EXTERNAL SURFACE OF THE BRAIN TO THE SCALP

To represent these from every point of view, I have selected the composites showing views of the skin and brain from eighteen different heads: Plates 14 to 17 and Plate 27, Fig. 1, for the adult side series, and the same series in children, Plates 18 and 19. For the series from the top the relations are shown in Plates 28, Figs. 1 and 2; 29, Fig. 1; and 32, Figs. 1 and 2 in the adult; and for children in Plate 31, Figs. 1 and 2. In the back series the relations are shown for the adult in Plate 35 and for the child in Plate 37, while the relations from the front are shown (but not very well) in Plate 42. The relations of the circumferential tape to the underlying parts of the brain can be read from Plates 14 to 19, and in 35, 37, and 42. It lies underneath the frontal lobe, save a portion of its orbital surface, meets the anterior extremity of the temporo-sphenoidal lobe at measurements varying in the adult from 3 $\frac{1}{4}$  to 4 inches (Plates 14 to 17), and in children from 2 $\frac{1}{2}$  to 2 $\frac{3}{4}$  inches (Plates 18 and 19), that is at distances varying with the circumference of the respective heads. The anterior end of this lobe sinks into the middle fossa of the base of the skull in front of the petrous portion of the temporal bone to the extent of one inch below the tape, the lower surface of the lobe, as seen in Plate 42, being on a level with the floor of the orbital cavity. The tape then passes along slightly above the lower margin of this lobe at its most curved portion, and also to a greater extent above the lower margin of the occipital lobe, as can be seen in Plates 14 to 19, 35 and 37.

The relations of the median longitudinal tape to the brain surface are displayed in Plates 28



(Figs. 1 and 2), 29 (Fig. 1), 31 (Figs. 1 and 2), 32 (Fig. 1), and in 35, 37, and 42. These relations require no explanation, corresponding, as they do, to the position of the superior longitudinal sinus.

The vertical relations of the lateral longitudinal tape are seen in Plate 27, Fig. 1, where it crosses in order from behind forwards the superior occipital, the second annectant, and the angular gyrus slightly below its upper border; crosses the supramarginal convolution also, but to a less extent than the angular; then passes over the two central convolutions below their middle, then comes into relation with the posterior portion of the inferior frontal gyrus, and finally crosses the second and first frontal gyri, as shown in Plate 42. The exact posterior relations of the tape are displayed in Plates 35 and 37.

The relations of the median transverse tape are seen from the side in Plates 14 to 17 and 27, Fig. 1, in the adult, 18 and 19 in the child; from the top in Plates 28 and 29, Fig. 1, in the adult, and in 31, Fig. 1 and 2, in the child: these are fixed and constant for all the series. The tape passes upwards from the circumferential one over the middle and superior temporo-sphenoidal convolutions, over the sylvian fissure, then always crosses the lower portion of the posterior central convolution, then the anterior central one, and finally ends in the manner seen in the top views by crossing the posterior extremity of the first frontal gyrus slightly anterior to its origin from the median end of the anterior central gyrus.

Those of the anterior transverse tape are seen in the same plates, and it will be found to pass over parts of the middle and superior temporo-sphenoidal convolutions, the anterior end of the sylvian fissure, the pars triangularis of the inferior frontal convolution, the middle frontal, and, lastly, the superior frontal, anterior to its centre.

The relations of the posterior transverse tape are also seen in the same plates; it passes laterally upwards over the middle temporo-sphenoidal convolution, then over the posterior border of the superior temporo-sphenoidal as this gyrus passes upwards to become continuous with the supramarginal, then over the angular, and its exact median relations can be judged from Plate 32, Fig. 1, where it ends by lying over the superior parietal lobule, about one inch in front of the parieto-occipital fissure. This posterior oblique view has not been represented in the children's heads, but the relations can be judged of from Plates 18 and 19; neither has the exact vertical relations of the median portion of the anterior transverse tape been shown. That would have required a head embedded up to the level of the posterior transverse tape; the vertical relations of the gyri of the frontal lobe can, however, easily be determined from the side views. All the relations of the various tapes, as can be seen by a glance at the several heads, are the same in the young and in the adult, and exhibit in a very striking manner the proportional relationships of the external surface of the brain in heads varying from  $14\frac{1}{4}$  to  $23\frac{1}{2}$  inches in circumference.

Before enumerating the portions of the cortical surface contained in the median and lateral spaces, into which the scalp surface is divided by the tapes, I shall describe the relations which the central sulcus, the fissure of Sylvius, and the parieto-occipital fissure bear to these tapes.

These relations vary according to the general rule already stated, and can be reached without any difficulty if this is kept in mind.

The median extremity of the central, or Rolando's sulcus, varies on the median longitudinal tapes from  $6\frac{1}{2}$  to  $7\frac{1}{2}$  inches from the root of the nose (Plates 28, Figs. 1 and 2, and 29, Fig. 1) in the adult, and in children from the  $4\frac{7}{8}$  to the  $5\frac{1}{2}$  inches (Plate 31, Figs. 1 and 2).

Its lateral or inferior extremity is always found slightly in front of the median transverse tape, and at a level on the latter varying from 4 to  $4\frac{3}{8}$  inches in the adult, and from  $2\frac{3}{4}$  to 3 inches in the child, from the middle line of the head (Plates 14 to 19).

The parieto-occipital fissure varies on the median longitudinal tape in the adult from  $9\frac{1}{2}$  to  $10\frac{5}{8}$  inches from the root of the nose, and in children from  $6\frac{7}{8}$  to  $7\frac{7}{8}$  inches, in Plate 32, Fig. 1, for the vertical prolongation of the long axis of the fissure to the scalp; Plate 35 for the horizontal relation of its extremity, and the top views for the vertical relation of its extremity in the adult; Plate 37 for the horizontal relation of its extremity to the scalp in the child.

This fissure has not the fixed and constant character of the central sulcus, being often bifid at its extremity, and unsymmetrical as regards position in the two hemispheres of the same head (Plate 37), as already noted by Hare, so that it cannot be depended upon in the same manner as Rolando's



sulcus. It will be noted that the fissure lies slightly anterior to the lambdoid suture, the latter varying on the tape from  $9\frac{3}{4}$  to  $11\frac{1}{8}$  inches, while the former varies from  $9\frac{1}{2}$  to  $10\frac{5}{8}$  inches.

The fissure of Sylvius has the course and relations to the transverse tapes shown in Plates 14 to 19. The middle of its horizontal limb can be found along the median transverse tape, slightly over one inch from the circumferential one, or, if measured from the mid-sagittal line of the head, from  $4\frac{1}{4}$  to  $4\frac{1}{2}$  inches, and in children from 3 to  $3\frac{1}{4}$  inches. The beginning of the horizontal limb of the fissure can be reached along the anterior transverse tape,  $1\frac{1}{4}$  to  $1\frac{1}{2}$  inch from the circumferential one, or from the middle line of the head from 4 to  $4\frac{1}{2}$  inches, and in children from  $2\frac{3}{4}$  to  $3\frac{1}{4}$  inches. The posterior tape does not come into relation with the fissure at all.

In consequence of the change in the squamous suture from a linear one in the child to an overlapping one in the adult, the relation of the fissure to the suture, or what is called the suture, is apparently not a fixed one. The line of junction of the upper margin of the squamous part of the temporal with the external surface of the parietal bone has nearly the same position as the horizontal limb of the fissure backwards as far as the median transverse tape; beyond it the suture has no relation to the fissure. In front of the median tape, however, the fissure is practically at the same level as the suture, although absolutely it may either fall slightly above or slightly below the fissure, especially at the position of the anterior transverse tape, this depending upon the amount of overlap of the parietal by the squamous part of the temporal bone.

It has already been noted that the lower borders of the parietal bones are the comparable parts in the young and in the adult, and that their relations to the underlying portions of the brain are the same, falling in both considerably below the level of the fissure of Sylvius.

I pass now to the enumeration of the cortical contents of the spaces marked off by the tapes on the skin. Those of the lateral spaces are seen in Plates 14 to 19, the median spaces in Plates 27, Fig. 1; 28, 29, Fig. 1; and in 31, Fig. 1 and 2; the third and fourth median spaces in Plate 32, the fourth median and lateral spaces from the back in Plates 35 and 37, and the first median and lateral spaces from the front in Plate 42.

A glance at the side or top views in as many different heads, young and old alike, will show that the contents are practically similar in all; in truth, the manner in which the tapes divide the brain into like areas at different periods of life is astonishing.

In the first lateral space are found portions of the superior, middle, and inferior frontal gyri and the orbital convolutions in part, a division of the vertical, and the beginning of the horizontal limb of the fissure of Sylvius, the anterior extremity of the temporo-sphenoidal lobe and a small part of the upper and middle temporo-sphenoidal convolutions.

In the second lateral space are found the lower portions of the central and precentral sulci, portions of the ascending frontal and parietal convolutions, the pars opercularis, and a portion of the pars triangularis of the inferior frontal convolution; also the sylvian fissure in part, and small areas of the superior and middle temporo-sphenoidal convolutions.

In the third lateral space are found the lower part of the post-central sulcus, and part of the posterior central or ascending parietal gyrus, the supramarginal and portions of the upper and middle temporo-sphenoidal gyri, and a corresponding part of the parallel sulcus.

In the fourth or posterior lateral are found the greater portion of the angular gyrus, the terminations of the middle and a part of the inferior temporo-sphenoidal gyri with their continuations as second, third, and fourth annectants, and portions of the superior, middle, and inferior occipital convolutions and the corresponding sulci.

The contents of the median spaces are illustrated by the top, front, back, obliquely from the side and obliquely from the top views. In the anterior or first median space are found the smaller divisions of the superior and middle frontal convolutions.

In the second median are found the larger divisions of the superior and middle frontal gyri, a part of the precentral or ascending frontal convolution, with the superior frontal and upper ramus of the precentral sulcus.

In the third median are found the posterior end of the superior frontal convolution, the greater



part of the anterior and posterior central gyri with the corresponding portion of the central or Rolando's sulcus, a great part of the intraparietal sulcus, a small portion of the supramarginal, with a larger part of the angular gyrus, and the greater portion of the superior parietal lobule. Plate 32, Fig. 1, which was meant to illustrate this and the succeeding median space, shows the variations that may occur; the head was not symmetrical, one of the lateral longitudinal tapes being half an inch longer than the other. This asymmetry is also shown by the convolutions of the adjacent hemispheres, there being four well-marked central convolutions on the one side but not on the other; the intraparietal sulcus being in this manner bridged over by the union of the superior parietal lobule with the angular and supramarginal gyri.

In the posterior median space (Plates 32, 35, and 37) are found the posterior part of the superior parietal lobule and its continuation, the first annectant; a part of the angular and second annectant gyri; a portion of the intraparietal and its continuation, the superior occipital sulcus; also the superior occipital gyrus and the parieto-occipital fissure.

In this enumeration of the contents of these spaces I have entered into no detail, as the plates can be read by those who may avail themselves of this work with as much ease as I could describe them.

#### 4. RELATIONS OF THE CENTRAL LOBES AND LATERAL VENTRICLES TO THE SCALP

The plates illustrating these are from 20 to 23, 27 (Fig. 2), 30, 31 (Fig. 3), and 38. A glance at the plates will show the same proportional regularity in the position of the central lobes to the scalp as was the case with the several areas of the external surface of the brain.

The stem or peduncle of the island lies in the first lateral space slightly above the level of the circumferential tape. The entire central lobe, with the corona radiata, occupies portions of the first, second, third, and encroaches slightly on the fourth lateral space. The amount of corona in the latter depends on the obliquity of the incision through its occipital portion. The incision follows roughly the junction of the commissural with the peduncular system of fibres, as well as the curve of the caudate nucleus. This obliquity is somewhat greater in the dissection illustrated in Plate 21, so that it occupies more of the fourth lateral space than in the other heads. The upper limit of the island from the middle line of the head falls on the mid-transverse tape at 4 inches in the adult, and at  $2\frac{1}{2}$  inches in the child; in the line of the anterior transverse tape at from  $3\frac{1}{2}$  to  $3\frac{3}{4}$  inches in the adult, and in children at  $2\frac{1}{4}$  inches.

The anterior horn of the lateral ventricle occupies part of the first lateral space, the body of the ventricle portions of the second and third lateral spaces, while the cavity of the posterior horn can be readily reached from the fourth lateral space, as I have already indicated when describing this particular serial dissection. Plate 27, Fig. 2, shows the relations of the central lobe and lateral ventricle to the lateral longitudinal tape, as well as the extent of hemisphere left after the curved incisions have been made to lay bare the course and extent of the body and cornua of the ventricle.

The descending horn and the hippocampus major reaches within an inch of the anterior extremity of the temporo-sphenoidal lobe, and can be reached at the level of the circumferential tape. The curve formed by the floor of this horn and that of the posterior one depends chiefly on the amount of curve on the under surfaces of the temporal and occipital lobes, as these lie on the tentorium and the petrous portions of the temporal bones. The amount of curve on these surfaces varies, as can be seen in Plate 20, where the surfaces are nearly straight, but are more curved in Plates 21 and 22.

The relations of the central lobes from above are seen in Plates 30, Fig. 1 and 2, for the adult, and in 31, Fig. 3, for the child. They occupy proportional areas of the second and third median spaces in the three heads illustrated, and extend on either side of the middle line from  $1\frac{1}{8}$  to  $1\frac{3}{8}$  inch in the adult, and to  $1\frac{1}{2}$  inch in the child.

The position and relations to the scalp surface of the caudate nuclei, the optic thalami, and the other parts in the lateral and third ventricles can be read from the views.

In Plate 22 the circumferential tape is placed a little too high behind, somewhat over the inch above the external occipital protuberance, and the same in Plate 25, which is from the same head.



## 5. RELATIONS OF THE INTER, MID, HIND, AND AFTER BRAIN, OTHER STRUCTURES, AND THE MEDIAN SURFACE OF THE FORE-BRAIN, TO THE SCALP

These are exhibited from the side in Plates 24 to 26; the mid and hind brain from the top in Plate 30, Figs. 1 and 2, and 31, Fig. 3; the hind brain and cervical spinal cord and nerve-roots from the back in Plates 35, 37, and 38; and the central lobes, the inter, mid, hind, and after brain, with certain cranial and spinal nerves, in Plates 39, 40, and 41.

The relations of the lower parts of the lateral lobes of the cerebellum are seen in Plates 14 to 17 for the adult and in 18 and 19 for the child, in its entirety in Plates 25 and 26 from the side, and in 39 and 40 from the back. Its lower margin falls 2 inches below the circumferential tapes, or  $5\frac{1}{4}$  to  $5\frac{1}{2}$  inches vertically from the middle line of the head (not measured on the round); in children it falls  $1\frac{1}{4}$  inch below the tape, or  $3\frac{3}{8}$  to  $3\frac{7}{8}$  inches vertically from the middle line of the head; its upper border rises into the fourth median and lateral spaces, and its vertical height measures  $2\frac{1}{4}$  inches in the adult, and from  $1\frac{3}{8}$  to  $1\frac{3}{4}$  inch in the child. Its anterior border reaches forwards as far as a vertical falling slightly behind the position of the mid-transverse tape. Its width (Plates 37, 38, 39, and 40) is  $4\frac{1}{4}$  inches in the adult and 3 inches in the child.

The relations of the tapes to the median surface of the hemisphere, Plates 24, 25, and 26, are practically identical. The circumferential one passes over the lower part of the marginal and the hippocampal gyri, over the lingual lobule, and comes into relation with the posterior extremity of the calcarine fissure.

In the fourth lateral space are found not only the upper part of the cerebellum, but also the cuneus, portions of the lingual and quadrate lobules, and the gyrus fornicatus as it passes downwards to become continuous with the uncinate convolution, and in addition the parieto-occipital fissure.

In the third lateral and median spaces are seen the remaining portion of the quadrate lobule, a part of the gyrus fornicatus, the paracentral lobule, the beginning of the marginal convolution, and the calloso-marginal sulcus.

The first and second lateral and the second median spaces contain the remaining portions of the marginal and fornicate gyri, and the calloso-marginal sulcus, while the relation of the mid-section of the corpus callosum to the transverse tapes is seen in the three plates, and in the adult occupies portions of the four lateral spaces, but more of the first than of the fourth lateral one. These relations are alike in all the adult heads, and the older children, but in the one of four months, Plate 26, the corpus callosum fails to reach the fourth lateral space.

The parieto-occipital fissure is also slightly nearer the posterior transverse tape in this child than in the adult heads. These are the only points of difference in the proportional relations which I have found to exist in the young and in the adult, and these are but slight.

The relations of the inter and mid brain with the pons and medulla are exhibited in these plates, and the particular inch or half-inch at which they may be struck from the external surface can be read from the tapes; and their relations from the top in Plate 30, Figs. 1 and 2, will be found to be proportional, as was the case with the several divisions of the cortical surface.

Again, the relations of the islands, the inter, mid, and hind brain with the medulla are illustrated in Plates 38, 39, 40, and 41, from the back, and follow the same rule.

In addition to the relations of the external and central parts of the brain to the scalp, these views give accurate guides to the surgeon to reach every cranial and spinal nerve shown in them. He has only to glance at Plates 25, 26, 38, 39, 40, and 41 to obtain the position of any of the cranial as well as the cervical or upper dorsal nerve-roots to the tape measurements, in the adult or in the child, from the root of the nose; the median longitudinal tape in all the back views being prolonged to the lower part of the neck if adult, or to the lumbar region in children. In glancing at the plates he can easily detect the small first cervical; then the others can be read off in their order as low as the third dorsal in the case of the adult, or to the lower lumbar in the case of the children.

In this short description of the relations of the deeper lying structures to the scalp surface, I have purposely refrained from entering into wordy detail. To the educated eye these plates require little, if any, explanation.



## V.—SUMMARY AND GENERAL RULES

Were I a surgeon, called upon to open the living head at any age after birth, I should proceed as follows:—

If the seat of brain lesion is situated on the lateral aspect of the external surface of the brain—that is, below the line of the temporal ridge—I would depend on Plates 14 to 19; if it is between the mid-sagittal line of the head and the temporal ridge externally, I would select Plates 28, 29, and 31; if it is directly underneath the ridge itself, I would depend on Plate 27; if it is situated behind, I would select Plates 32, 35, 37, or 38; and if it is in front, I would turn to Plate 42, or the anterior portion of the side or top series of plates. After locating the area to be operated on to the median or lateral longitudinal tapes, or to the circumferential one by a glance at any of the above-mentioned plates, then, as the circumference of the illustrated head is to the circumference of the living one, so is the position of the area on the above tapes in the illustrated head to the desired position of the same area in the living one.

As I have illustrated so many different heads with the circumference varying from  $20\frac{1}{4}$  to  $23\frac{1}{2}$  inches (after shaving the scalp), a maximum difference of  $3\frac{1}{4}$  inches, and as the average adult head to be operated on will not vary more, a glance at the plate illustrating the head with a circumference nearest the living one will be all that is necessary for the surgeon; so that the rule frequently mentioned, although it is well to know it, may almost remain a dead letter.

Should the surgeon desire to reach any of the central structures he will select the corresponding plates—those showing the relations of the central lobes and ventricle, or the others illustrating the relations of the inter, mid, hind, and after brain, the position of these following practically the same law as in the case of the cortex.

It is unnecessary that the surgeon should apply all the tapes to the scalp which appear on the plates; the median longitudinal, or the circumferential will suffice, as the position of any area can be readily enough found on verticals from the latter, or on lines parallel to the mid-transverse tape on the former.

It would not be difficult for an instrument-maker to design an apparatus that could be fitted on the vault of the head in the position of the tapes, and with corresponding measurements, somewhat similar to Wilson's cyrtometer, or other contrivances at present in use for locating the position of the central or Rolando's sulcus.

## VI.—BIBLIOGRAPHY AND SLIGHT HISTORY

It is not my intention to give a detailed history in this work of the various methods that have hitherto been employed in elucidating the relations of the cortex to the cranial vault or to the scalp. No one has, excepting, to a small extent, Féré and Sir W. Turner, attempted to deal fully, so far as I know, with the relations of the central parts of the brain to the bone, or scalp surface. The main facts are well known to operating surgeons. I shall, however, give a more or less chronological list of the most important of the papers that have been published dealing with this subject.

The operation of trepanning seems to have been begun before the dawn of history itself, as shown by Broca at the sitting of the French Academy of Medicine on June 19, 1877. At a meeting held nearly ten years before Broca's communication, on July 9, 1867, Squire had presented to the Academy a number of crania, which afforded evidence that it had been practised by the Incas of Peru; and a week later Baron H. Larrey showed a collection of instruments which had been used by the Arabs for the operation. Mention of it is also to be found in the works of Hippocrates, Celsus, Galen, and other ancient authors; and Mr. Horsley delivered a lecture to the members of the Anthropological Institute (see Vol. 17 of their Journal) on 'Trephining in the Neolithic Period,' which was based chiefly on Broca's 'Crania.'



The opening of the cranial cavity, however, at these dates had little reference to the anatomy or physiology of its contents, and it only became possible to localise the several divisions of the brain either to the cranium or the scalp after these had been thoroughly established by the labours mainly of Burdach, Rolando, Valentin, Arnold, Huschke, Leuret, and Gratiolet, and it was with this latter author that the history of projecting the underlying brain on its bony or scalp surroundings may be said to have begun.

1. GRATIOLET: Leuret et Gratiolet, Anatomie comparée du système nerveux. Paris, 1839-57. Vol. ii. s. 124.
2. BROCA: Sur le siège de la faculté du langage articulé. 'Bullet de la Soc. Anat.' 1861, 2me série, t. vi. p. 340. Also Sur la topographie cranio-cérébrale ou sur les rapports anatomiques du crâne et du cerveau. 'Revue d'Anthropologie,' t. v. 1876. s. 193. And Mémoires sur le cerveau de l'homme et des primates, publiés avec une introduction et des notes par S. Pozzi, Paris, 1888.  
Broca drove pegs into the brain after boring holes through the bones; and in this way determined the relations of the upper end of Rolando's sulcus and the parieto-occipital fissure to the adjacent sutures.
3. BISCHOFF: Die Grosshirnwindungen des Menschen. 'Abh. der K. Bay. Akad. der Wissenschaften,' II. Kl., X. Bd., II. Abth. München, 1868. Followed the method of Broca.
4. ECKER: Zur Kenntniss der Wirkung der Skoliopädie des Schädels, &c. 'Archiv für Anthropologie,' Bd. ix. s. 61; and Ueber die Methoden zur Ermittlung der topographischen Beziehungen zwischen Hirnoberfläche und Schädel. Bd. x. of the same Archiv, 1878, pp. 233. Also Vortrag, in Baden Baden, 20 Mai, 1876, summarised in 'Archiv für Psychiatrie,' 1876.  
He also drove pegs after the manner of Broca, but through fixed points in the coronal suture (at bregma, stephanion, and pterion); also in the lambdoid at 15 m.m. from the middle line of the head, and midway between the middle line and the asterion; and, lastly, in the squamous suture at its highest part. In this way he determined the position of the central sulcus and the parieto-occipital and sylvian fissures.
5. SIR W. TURNER: 'Journal of Anatomy and Physiology,' vol. viii., 1874, pp. 142 and 359. This paper is well known, and has been summarised in most of the textbooks. The chief advance was the fixing of the supramarginal gyrus as the convolution of the parietal eminence.
6. FÉRÉ: Notes sur quelques points de la topographie du cerveau. 'Archiv de Physiol.' 1876, p. 247. Contribution à l'étude du développement du cerveau considéré dans les rapports avec le crâne. 'Bulletin de la Soc. Anat.' 1877. And Anatomie médicale du système nerveux. Paris, 1886.  
A summary of his work is given by Seguin in the 'Medical Record,' 1878, and copied by Ranney in his work on the Applied Anatomy of the Nervous System. Second Edition, New York, 1888.
7. SEELIGMÜLLER: Notiz über das topographische Verhältniss der Furchen und Windungen des Gehirns zu den Nähten des Schädels, in 'Archiv für Psychiatrie,' Bd. viii., 1877. He made windows in the bony roof, chiefly over the motor region.
8. HEFFTLER: Die Grosshirnwindungen des Menschen und deren Beziehungen zum Schädeldach. Communicated by Professor Th. Landzert (St. Petersburg) to the X. Bd. of the 'Archiv für Anthropologie,' p. 243.  
This is by far the most thorough piece of work that has been done in reference to this subject. He injects the heads after removal from the body from the carotids and vertebrae with a solution of chloride of zinc in spirit, with glycerine and carbolic acid added, then imbeds the head, places it under the drawing apparatus of Lucae, and takes the outline of the skin view on transparent paper. After removal of the soft parts, he does the same with the bone view, drawing it inside the skin outline on the same paper. He proceeds in this way taking dura, brain, and central lobes, until he has secured the outlines of the various views with different-coloured pencils in their natural relations to one another all on the same paper.  
For this work he used forty heads, ten for the profile view, ten for the vertical, ten for the frontal, and ten for the occipital—all in the adult. The paper is illustrated by four outline drawings, one from each of the above-mentioned aspects, which show the relations of the cortex and the central lobes to the sutures.
9. GIACOMINI: Topografia de la scissura di Rolando (Torino, 1878), quoted by Schwalbe in his Lehrbuch der Neurologie, p. 588.
10. FOULHOUZE: Recherches sur les rapports anatomiques du cerveau avec la voûte du crâne chez les enfants. Th. de Paris, 1876. I have only seen a summary of this in Virchow-Hirsch, Jahresbericht, XI. Jahrgang, I. Bd., which says that in children from the sixth month to the third year, the relations of the brain to the sutures are very different from those in the adult, but that they change little by little until the adult relations are reached.
11. J. L. CHAMPIONNIÈRE: Des localisations cérébrales. Rôles qu'elles peuvent jouer dans le diagnostic et le traitement des maladies cérébrales. 'Journ. de Méd. et de Chir. pratiques,' October, 1876. La trépanation guidée par les localisations cérébrales. The same, February 1877, et 'Bull. Acad. de Méd.' January 9, 1877.  
Modified slightly, but rests chiefly on Broca's method for localising the Rolandic line; he also modified Broca's instrument.
12. GAVOY: Atlas d'anatomie topographique du cerveau et des localisations cérébrales. Paris, 1882, with 18 plates. Shows the relations of the brain to the sutures, and contains a good list of French literature bearing on the subject.
13. HARE: In 'Journal of Anatomy and Physiology,' vol. xviii., pp. 175, introduces the principle of proportion for locating the mesial end of the sulcus of Rolando, that it is always 55 per cent. of the distance between the glabella and the external occipital protuberance, and also that the angle which the sulcus forms with the middle line is fairly constant. From the diagram which he gives, and the position of the posterior peg, I should be inclined to think that the maximum occipital point has been taken for the protuberance, a mistake easily made and one into which I fell in my first heads; had the peg been at the protuberance much more of the occipital and temporo-sphenoidal lobes would have been laid bare. In his final table the distance between the two fixed points is given as varying from 11 to 15 inches, and the mesial end of the sulcus as varying from  $6\frac{1}{10}$  to  $8\frac{3}{10}$  inches; in the largest of my heads  $23\frac{1}{2}$  inches circumference the mesial end of the sulcus is at  $7\frac{1}{2}$  inches from the root to the nose, and the external occipital protuberance at 14 inches.
14. REID: 'Lancet,' September 1884, p. 539. His diagrams are well known, and copied in many medical and surgical textbooks.



15. HORSLEY: Topography of the Cerebral Cortex, 'International Journal of the Medical Sciences,' vol. xciii. 1887. Adopts Professor Thane's method of locating the mesial end of Rolando's sulcus. The communication has been widely copied, coming from such a practical source.
16. SYMINGTON: Topographical Anatomy of the Child. Edinburgh: 1887. Gives one diagram, Fig. 11, p. 43, which shows the relations of the brain to the sutures in the child; and details observations mainly on the three fissures. He quotes Hamy's paper in the 'Revue d'Anthropologie,' p. 424, 1872, for the difference in direction of the sulcus of Rolando, and the relative size of certain parts of the frontal lobe in the young as compared with the adult. See the observations under the next heading, 17.
17. CUNNINGHAM: 'Lancet,' 1888, p. 1028. In comparing the brain in children and the adult, he mentions that the growth of the subjacent brain does not correspond with the growth of the bones, and quotes Féré and Topinard in support of this view; he exhibits models of two heads, in which differences could be easily seen. First, the frontal eminences lie over different portions of the frontal lobe in the young and in the adult. Secondly, the sulcus of Rolando is much more oblique, and lies further forward in consequence of the imperfect development of the frontal lobes, but that the lower end of the sulcus is gradually pushed backwards until it assumes its adult angle and position. Thirdly, the different relations in the young and in the adult between the squamous suture and the sylvian fissure as first noticed by Foulhouze, and he finally details the changes undergone by the temporo-sphenoidal lobe, how it is placed more horizontal in children, while in the adult its tip was turned downwards and inwards, giving its long axis a curved direction, and how its vertical depth in relation to that portion of the hemisphere above the sylvian fissure diminished uniformly and steadily as adult life was approached. He showed that Dr. Symington had accounted for this on mechanical grounds.  
He considered Reid's method very untrustworthy, and only a modification of Seguin's.
18. ANDERSON and MAKINS: 'Journal of Anatomy and Physiology,' vol. xxiii. p. 455. Corroborate Thane's guide for the mesial end of the sulcus of Rolando, and give many observations on the variations in the sutures and sulcus of Rolando.
19. L. A. MÜLLER: Ueber die topographischen Beziehungen des Hirns zum Schädeldach. Inaug. Dissert. Bern, 1889. This contribution is a very important one as far as the method serves, but badly illustrated. Shortly stated it is this: He adopts two fixed points, the glabella and the external occipital protuberance, connects these along the mid-sagittal line, and also horizontally, then divides these two measurements into ten equal parts (each of which may be subdivided), these forming 10, 20, 30, 40 per cent., &c., of the sagittal or horizontal measurement. He connects equal percentages on the mid-sagittal and horizontal lines by lines running laterally between the two. Then along these lines he makes one, two, three, or four trephine apertures at equal distances, and in this way fixes a particular part of the cortex for any particular trephine aperture on the connecting lines. The relation of the cortex to the apertures may be absolute, that is, the particular area may correspond to the aperture in every head; or it may be relative, that is, only a portion of the particular area may appear in the aperture.  
He gives formulæ for finding areas, such as the angular gyrus. Take of the sagittal and horizontal measurements each 65 per cent., then of the connecting line between the two, 57 per cent. for the centre of the aperture, which will lay bare the gyrus.
20. BRAUNE: In the third edition of his Atlas gives a profile and frontal view of the head, with remarks on Heffler's results.
21. KEEN: Brain Surgery, in vol. viii. of 'Buck's Reference Handbook of the Medical Sciences,' p. 201. This writer gives a *résumé* chiefly of English methods, and a description of the instruments used for locating mainly the sulcus of Rolando.
22. DANA: Cranio-Cerebral Topography, 'Medical Record,' January 1889, and 'Journal of Nervous and Mental Diseases,' June 1890. This author details a number of rules for reaching the several parts of the cortex, and also those of Féré for outlining the central ganglia.





VII.—LIST OF PLATES MADE FROM THE SERIAL AND COMPOSITE NEGATIVES, WITH DATE AND LENGTH OF EACH EXPOSURE, AND THE CIRCUMFERENCE OF EACH HEAD FROM WHICH THEY HAVE BEEN SELECTED.

Fourteen of the plates have been made from serial negatives, the remainder from composite negatives. The exposure for the first has been already indicated, the skin serial negatives requiring from forty to eighty minutes, the other serial negatives from sixty to one hundred and twenty minutes.

Plates 1, 2, 3, 4, 5, 7, 8,	are from Head 8,	Profile Series,	Circumference 23 in.
" 6, 9, 10,	" " 3,	" " "	" 23½ in.
" 29, Fig. 2,	" " 7,	Vertical "	" 22½ "
" 32, Fig. 2,	" " 11,	" Oblique Series,	" 21 "
" 34,	" " 4,	Occipital Series,	" 21½ "
" 36,	" " 5,	" " "	" 20¾ "

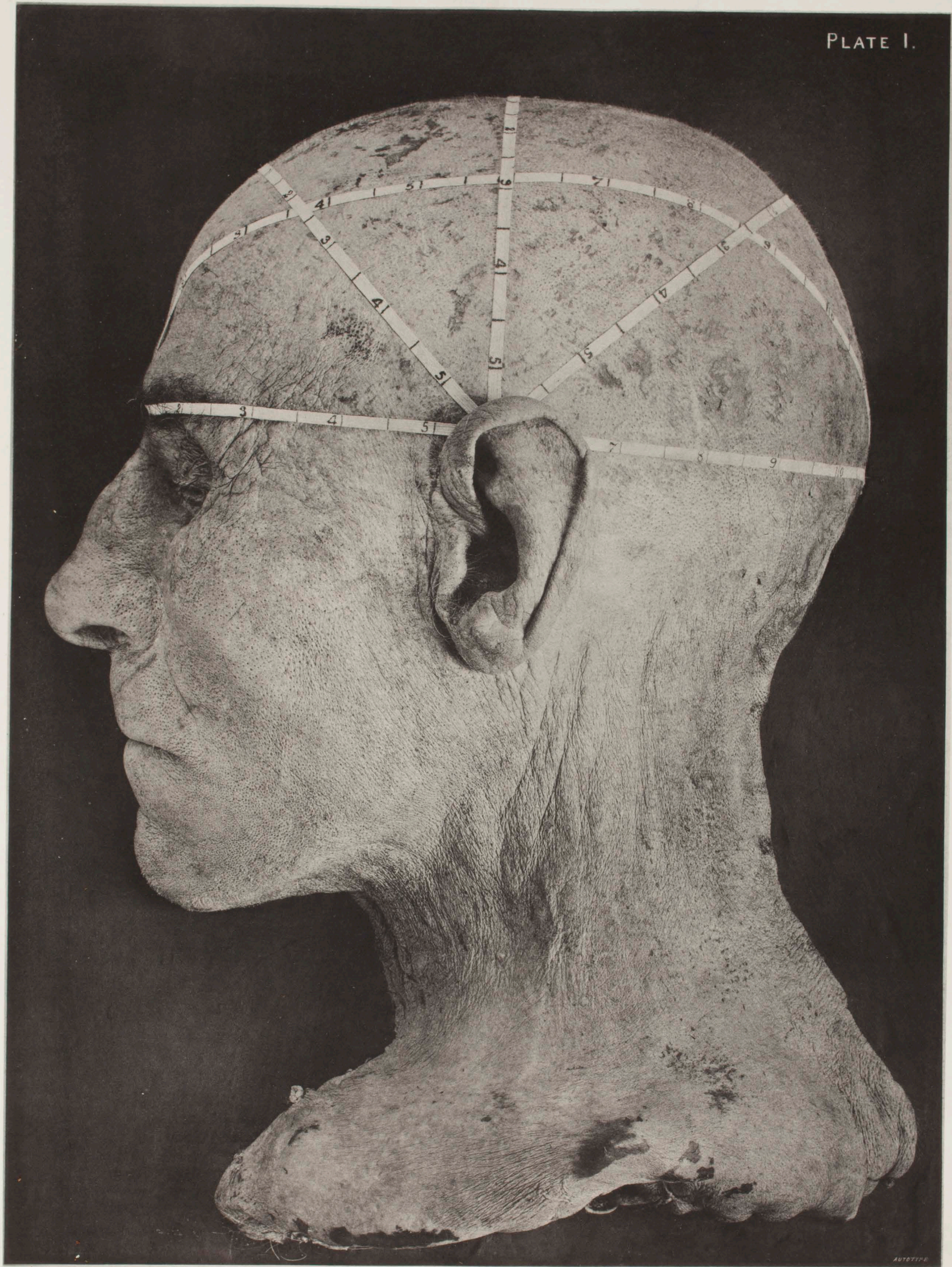
The remaining plates are composite, and have been made as follows:—

Plate 15	Skin 10 Minutes	(Wednesday, February 19, 1890	} Head 8, Profile Series, Circumference 23 in.
	Brain 45 "	(Saturday, " 22, "	
" 21	(Skin 9 "	(Wednesday, " 19, "	}
	Central Lobes 40 "	(Monday, " 24, "	
" 17	(Skin 2 "	(large diaphm.)	} " 3, " " " 23½ "
	Bone 5 "	Last week in June, 1889,	
	Brain 22 "	before mastery.	
" 11	(Skin 10 "	(Saturday, August 31, "	}
	Bone 30 "	(Monday, September 2, "	
	Brain 22 "	(not shown) (Wednesday, September 4, "	
" 14	(Skin 17 "	(Saturday, August 31, "	}
	Brain 60 "	(Wednesday, September 4, "	
" 20	(Skin 20 "	(Saturday, August 31, "	} " 4, " " " 21½ "
	Central Lobes 60 "	(Thursday, September 5, "	
" 24	(Skin 14 "	(Saturday, August 31, "	}
	Central Lobes 25 "	(not shown) " September 7, "	
	Median Surface 39 "	(Monday, " 9, "	
" 12	(Skin 7 "	(Monday, March 3, "	}
	Bone 45 "	(Tuesday, " 4, "	
" 13	(Skin 7 "	(Monday, " 3, "	} " 9, " " " 20¼ "
	Dura 35 "	(Wednesday, March 5, "	
" 16	(Skin 20 "	(Friday, December 27, "	}
	Brain 70 "	(Thursday, January 2, "	
" 18	(Skin 6 "	(Last week in July "	} " 10, " " " 16 "
	Bone 10 "		
	Brain 40 "		
" 19	(Skin 6 "	(Tuesday, April 22, 1890	}
	Brain 17 "	(Friday, " 25, "	
" 23	(Skin 6 "	(Tuesday, " 22, "	} " 11, " " " 14¼ "
	Central Lobes 15 "	(Friday, " 25, "	
" 26	(Skin 6 "	(Tuesday, " 22, "	}
	Median Surface 20 "	(Saturday, " 26, "	
" 27	(Skin 20 "	(Monday, January 20, "	}
Fig. 1.	Brain 45 "	(Wednesday, January 22, "	
Plate 27	(Skin 18 "	(Monday, January 20, "	}
Fig. 2.	Central Lobes 40 "	(Thursday, " 23, "	
Plate 28	(Skin 10 "	(Friday, August 2, 1889	} " 5, Vertical Series, " 22¾ "
Fig. 1.	Pia Mater 12 "	(Saturday, " 3, "	
	Brain 28 "	(Monday, " 5, "	




Plate 28	{Skin	19 Minutes	{Monday, October 28, 1889	} Head 6, Vertical Series, Circumference 20½ in.
Fig. 2.	{Brain	40 "	{Thursday, " 31, "	
Plate 30	{Skin	13 "	{Monday, October 28, "	}
Fig. 2.	{Central Lobes	30 "	{ " November 4, "	
Plate 29	{Skin	10 "	{Thursday, February 27, 1890	} " 7, " " " 22½ "
Fig. 1.	{Brain	43 "	{Saturday, March 1, "	
Plate 30	{Skin	8 "	{Thursday, February 27, "	}
Fig. 1.	{Central Lobes	40 "	{Monday, March 3, "	
Plate 31	{Skin	8 "	{ First week in August, 1889	}
Fig. 1.	{Pia Mater	10 "		
		{Brain	20 "	" 8, " " " 16¾ "
Plate 31	{Skin	8 "	{ First week in August, "	}
Fig. 3.	{Brain	15 "		
		{Central Lobes	28 "	
Plate 31	{Skin	23 "	{Tuesday, October 15, "	} " 9, " " " 16½ "
Fig. 2.	{Brain	45 "	{Monday, " 21, "	
Plate 33	{Skin	7 "	{Friday, April 4, 1890	}
	{Bone	30 "	{Monday, " 7, "	
" 37	{Skin	7 "	{Friday, " 4, "	} " 9, Occipital Series, " 16 "
	{Brain	20 "	{Tuesday, " 8, "	
" 40	{Skin	6 "	{Friday, " 4, "	}
	{Central Lobes	20 "	{Thursday, " 10, "	
" 35	{Skin	19 "	{Monday, January 6, "	} " 6, " " " 21¾ "
	{Brain	90 "	{Friday, " 10, "	
" 39	{Skin	17 "	{Monday, " 6, "	}
	{Central Lobes	60 "	{Tuesday, " 14, "	
" 38	{Skin	20 "	{Saturday, November 23, 1889	} " 5, " " " 20¾ "
	{Central Lobes	40 "	{Thursday, " 28, "	
" 41	{Skin	7 "	{Friday, April 18, 1890	} " 7, " " " 22 "
	{Central Lobes	15 "	{Tuesday, " 22, "	
" 42	{Skin	15 "	{Friday, August 23, 1889	} " 2, Frontal Series, " 21¼ "
	{Pia	27 "	{Tuesday, " 27, "	
	{Brain	28 "	{Wednesday, " 28, "	

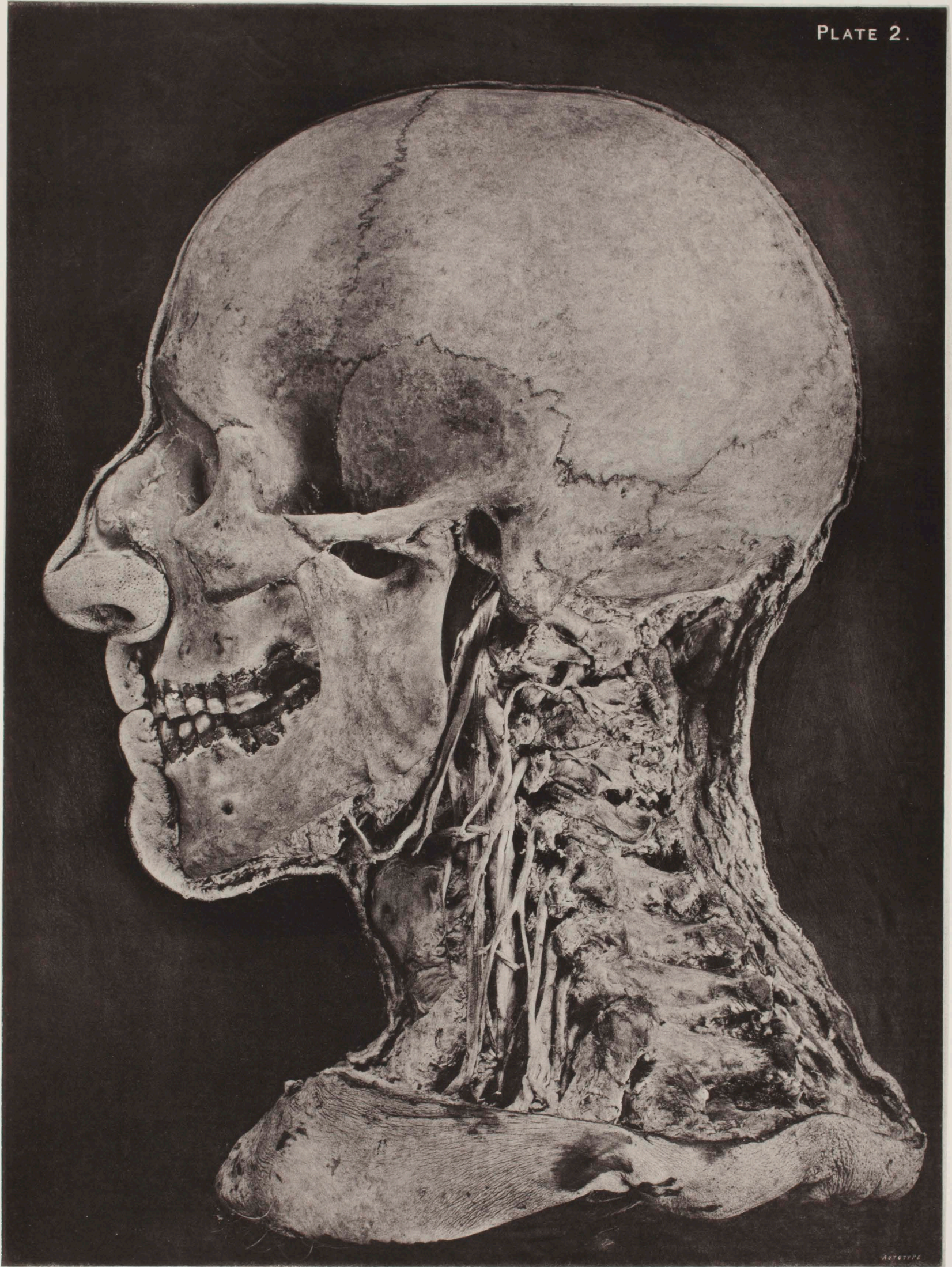











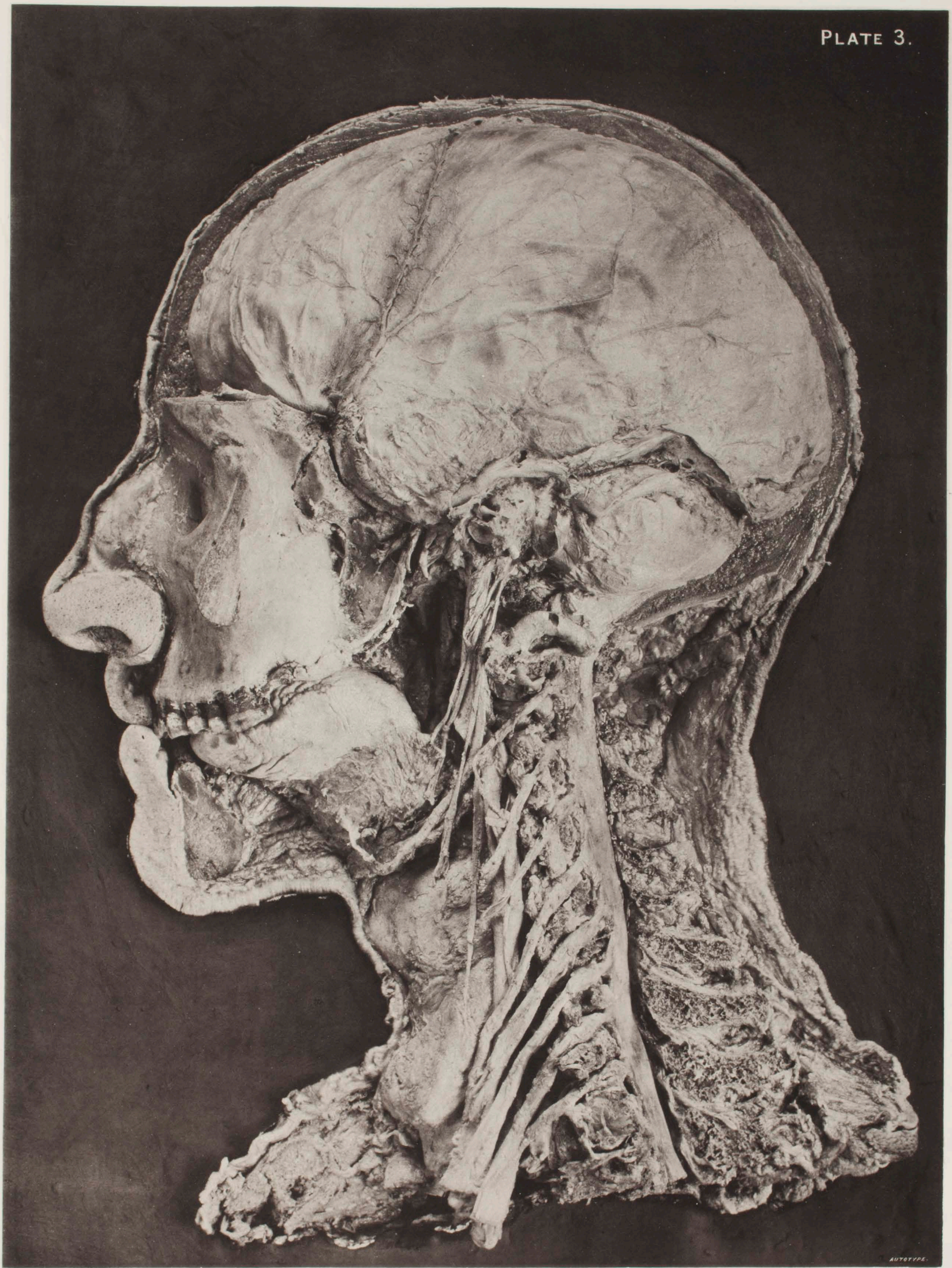
AUTOTYPE








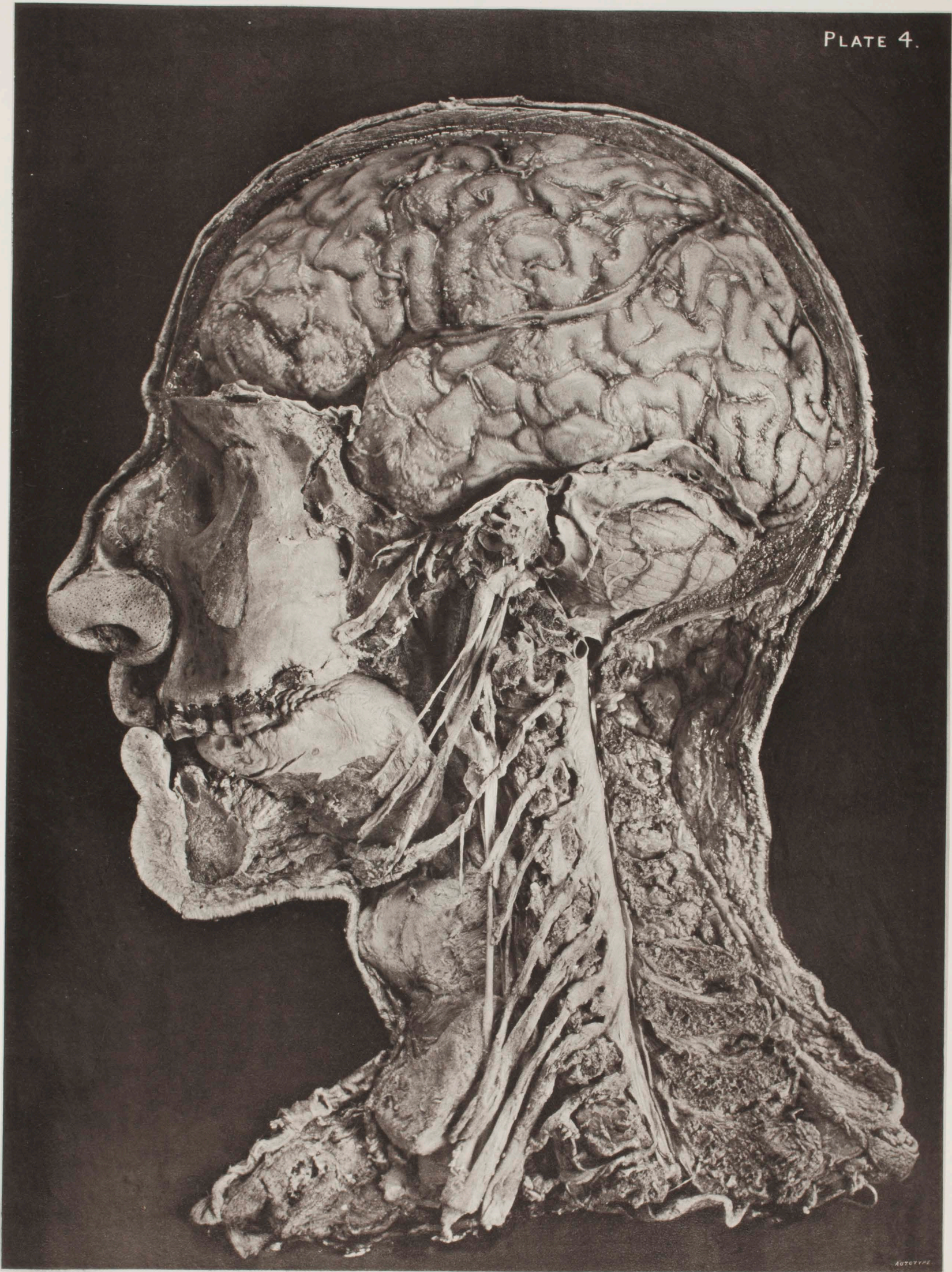
PLATE 3.








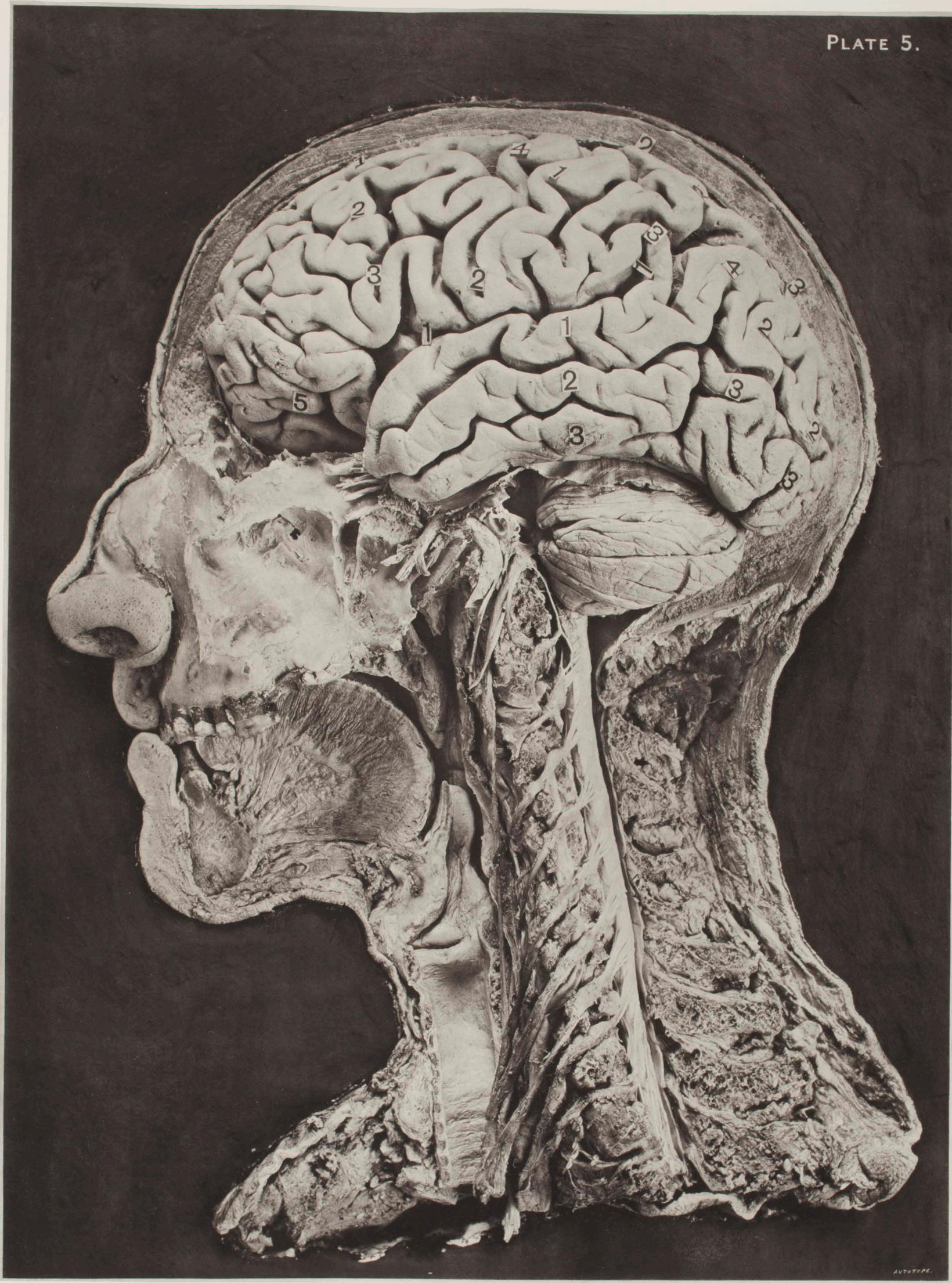









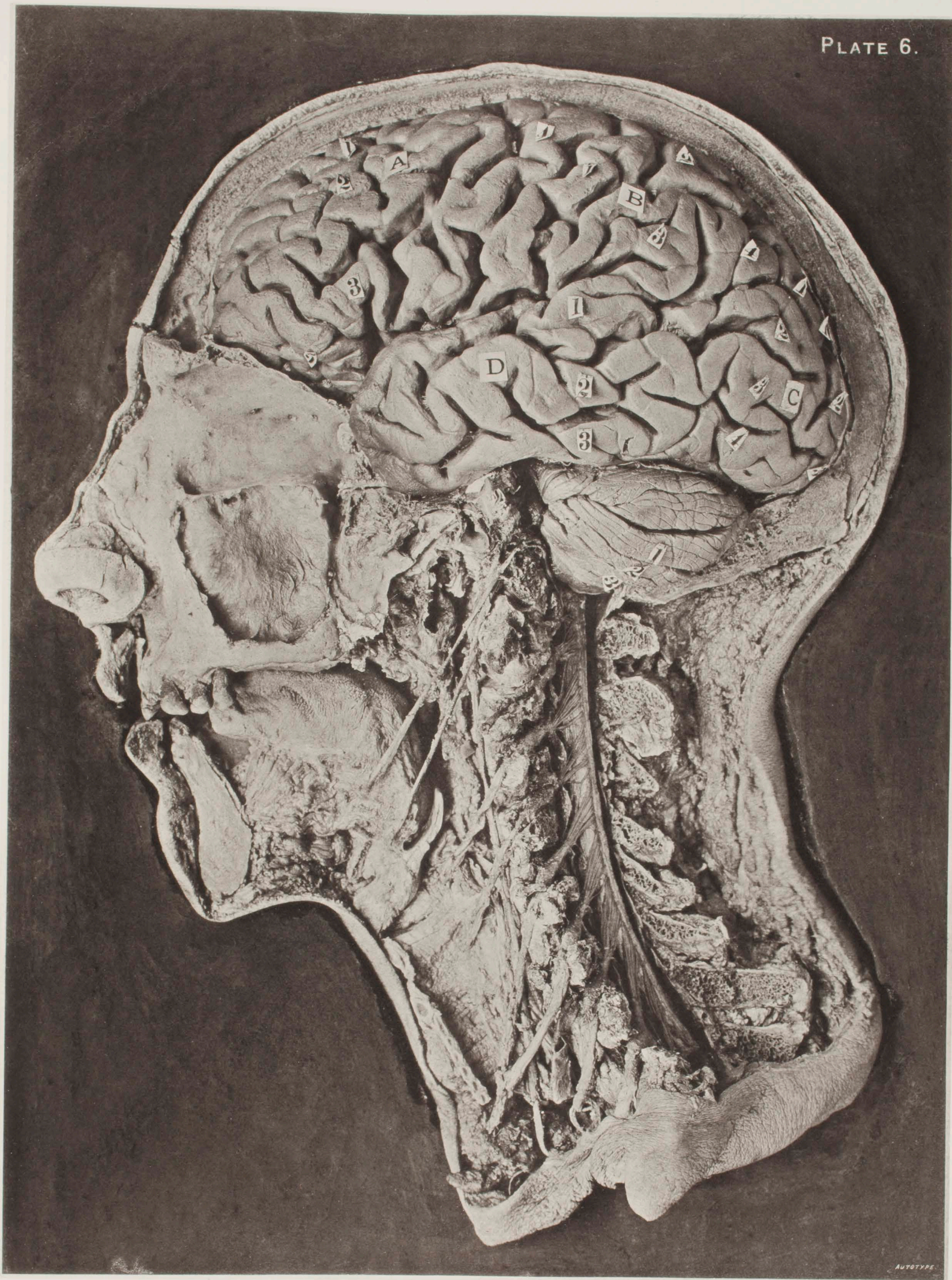








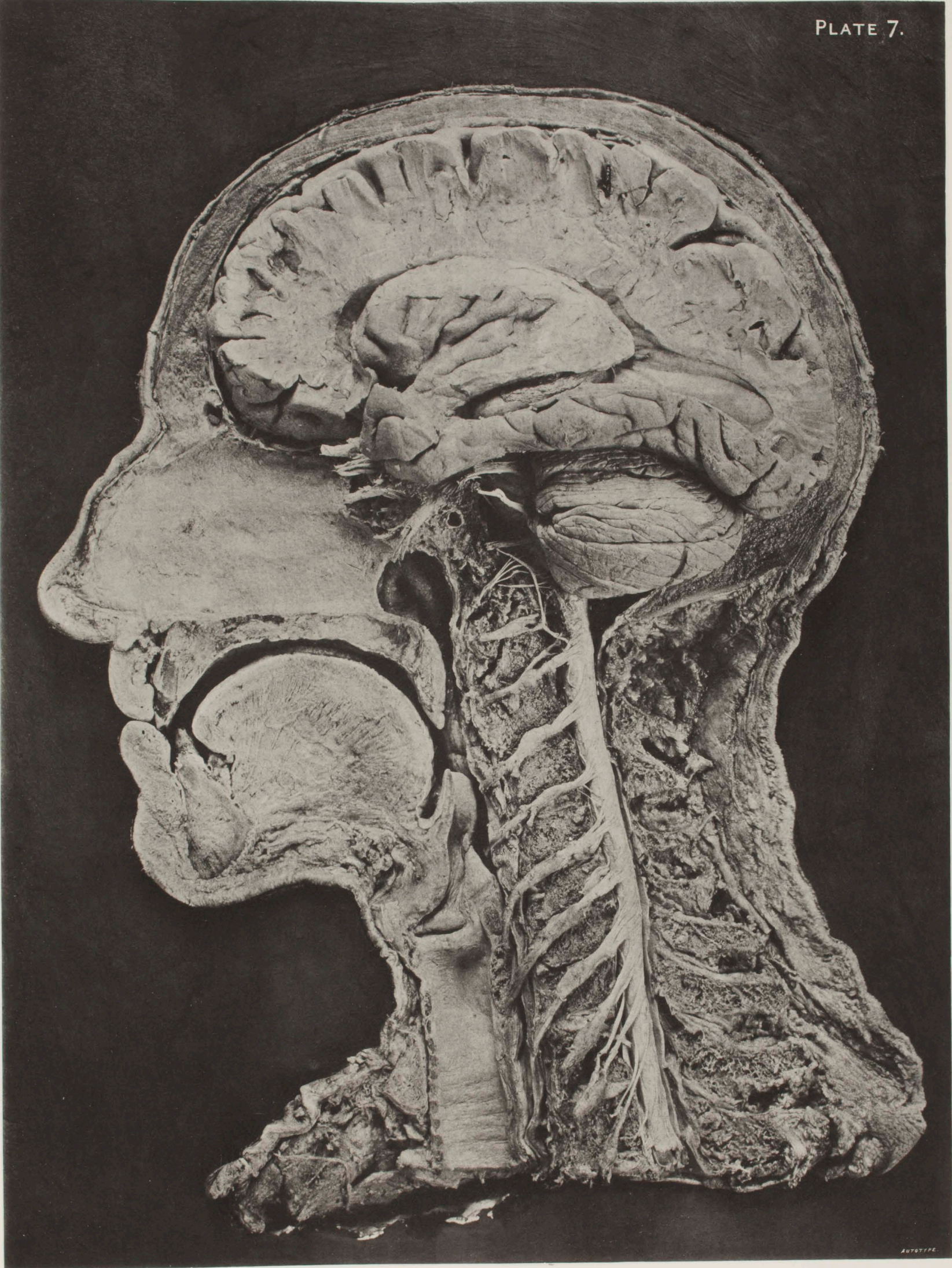






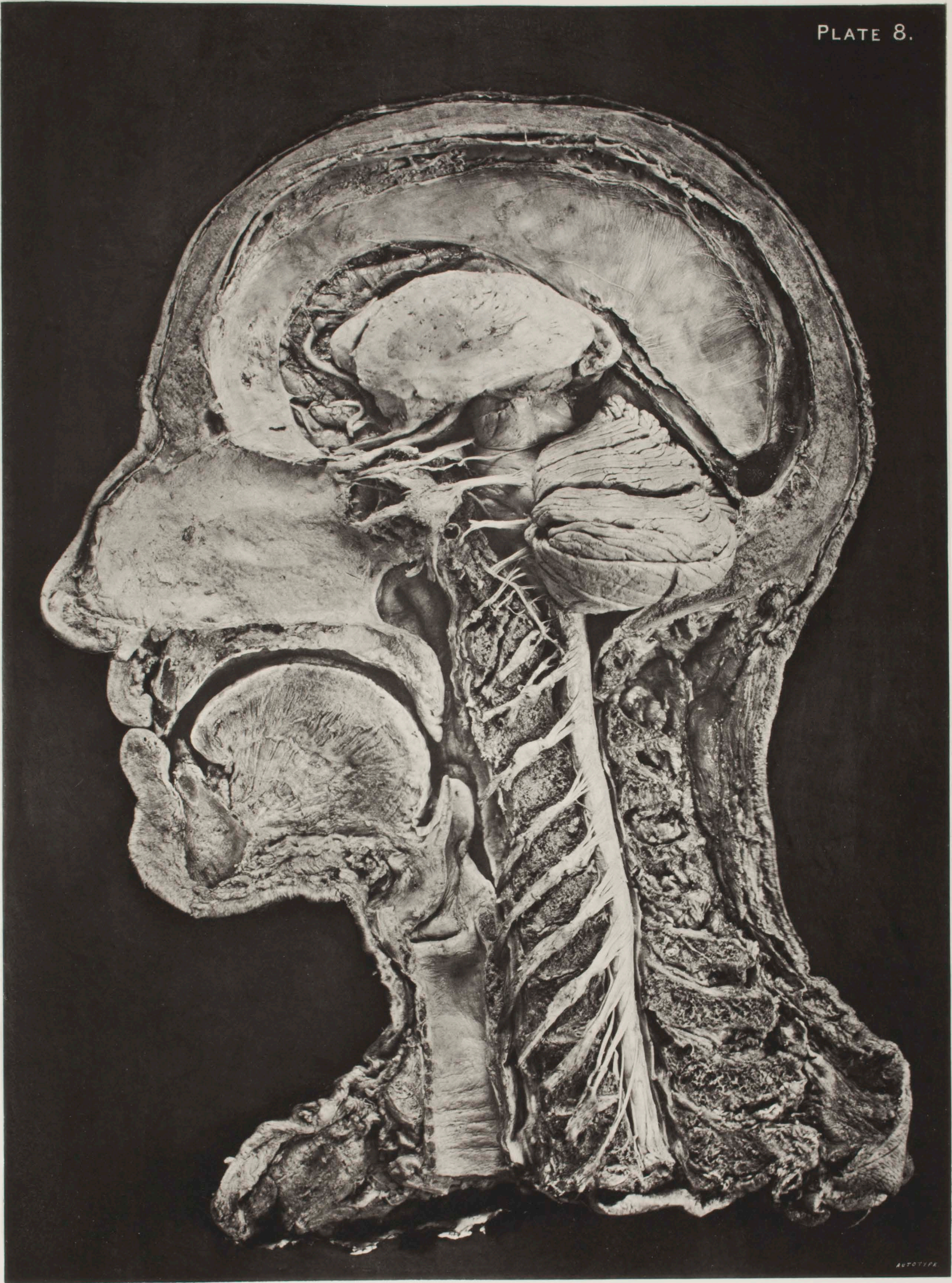











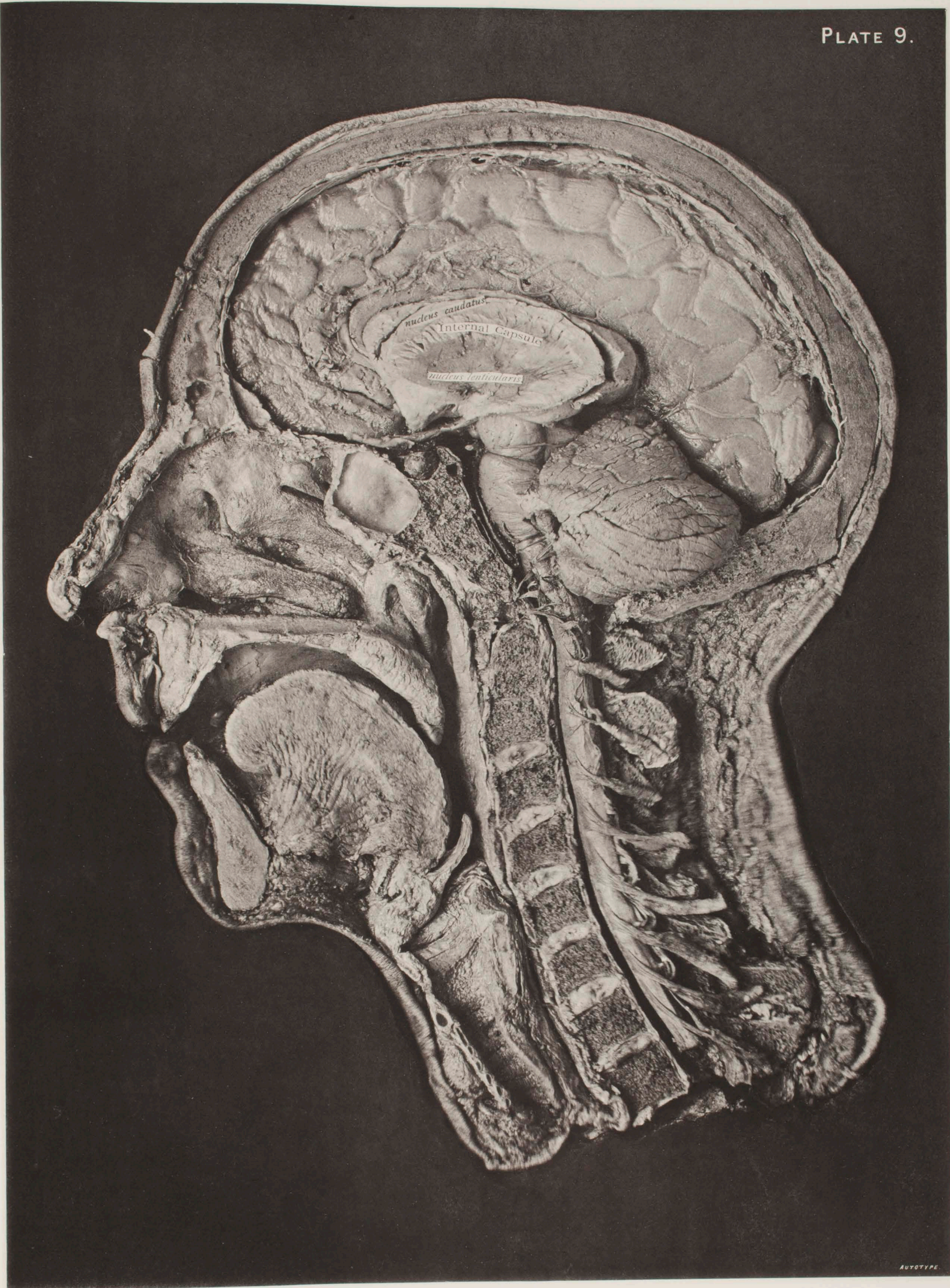

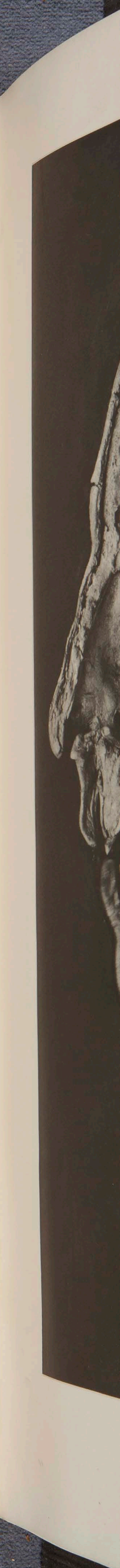







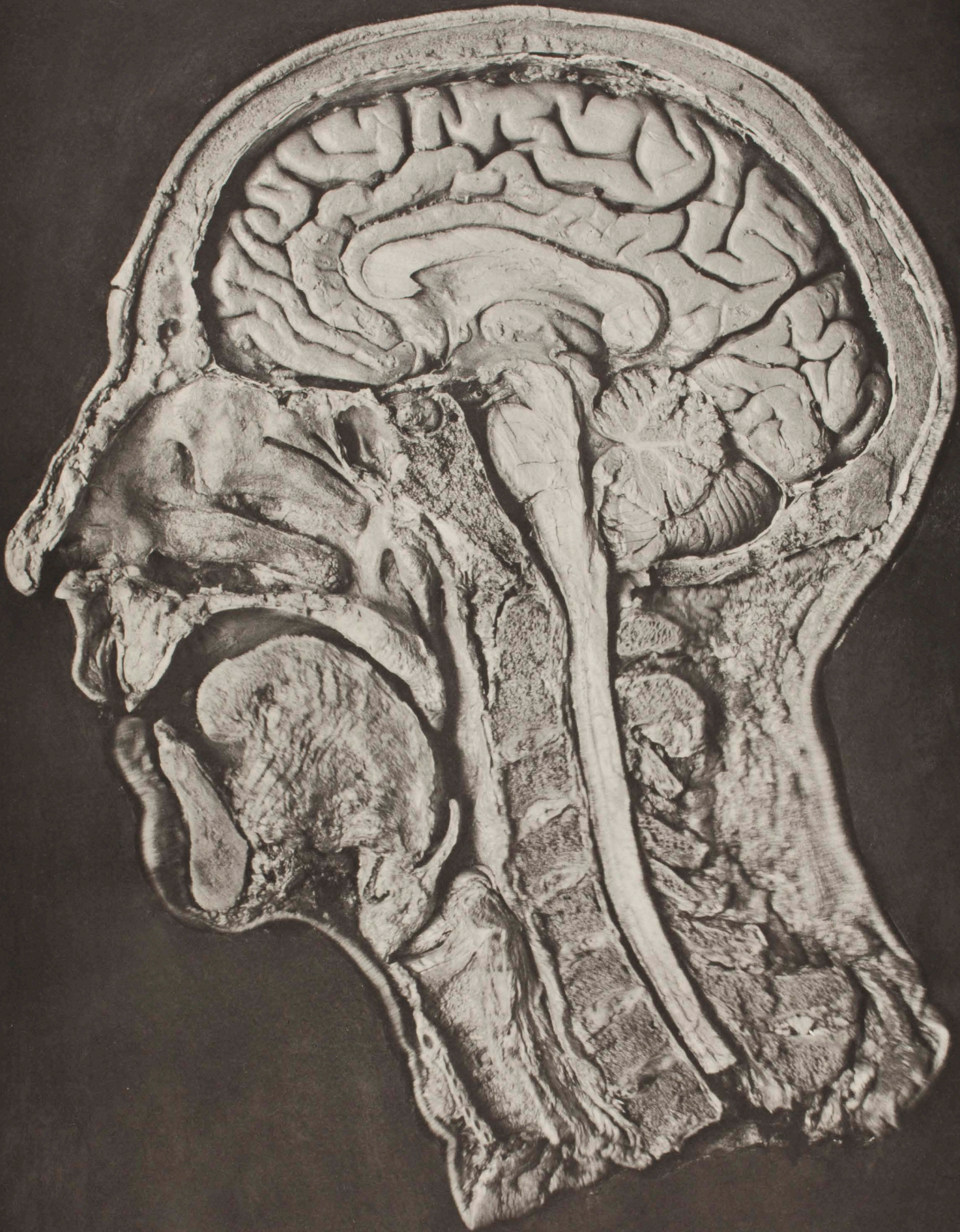





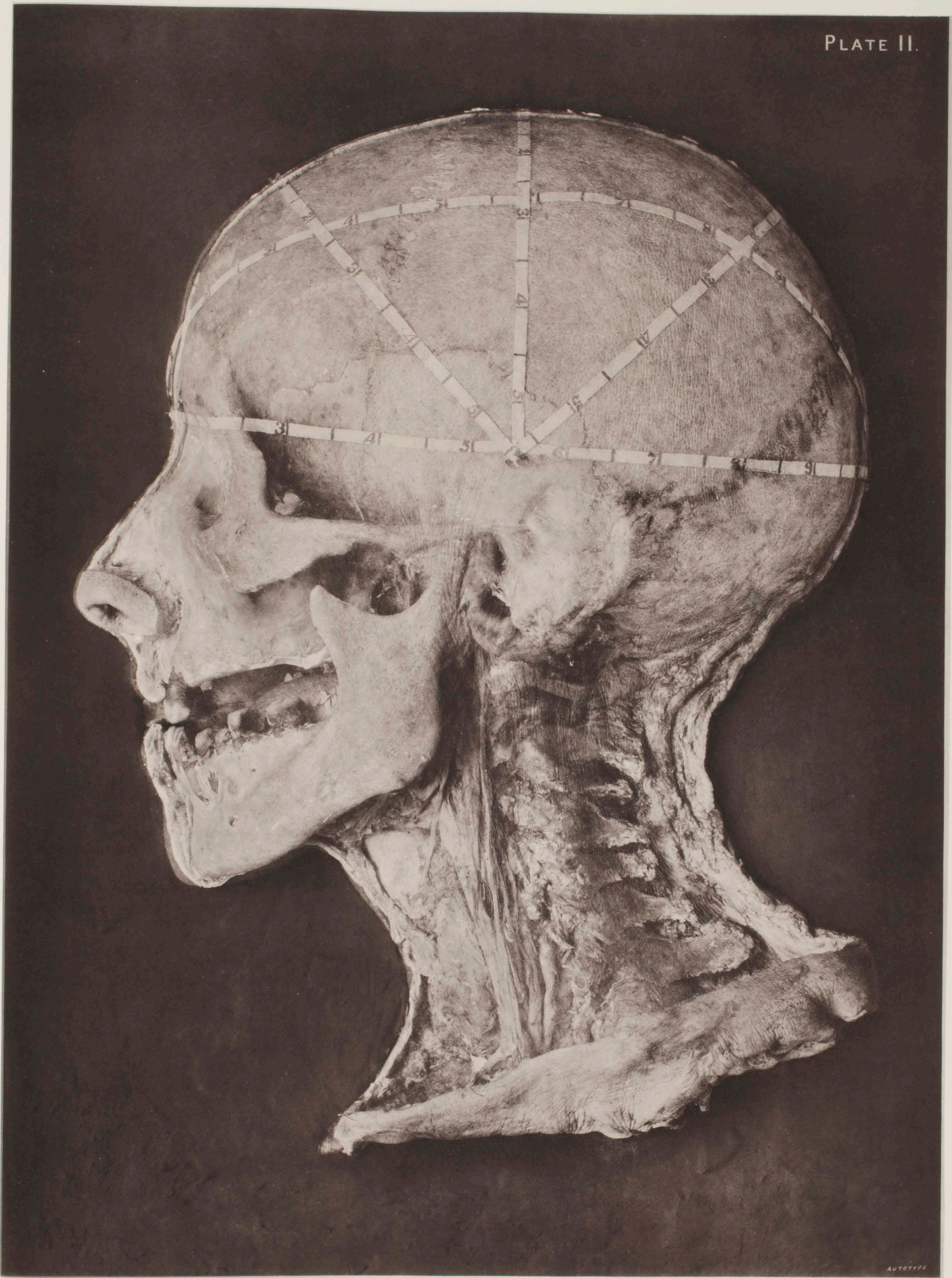








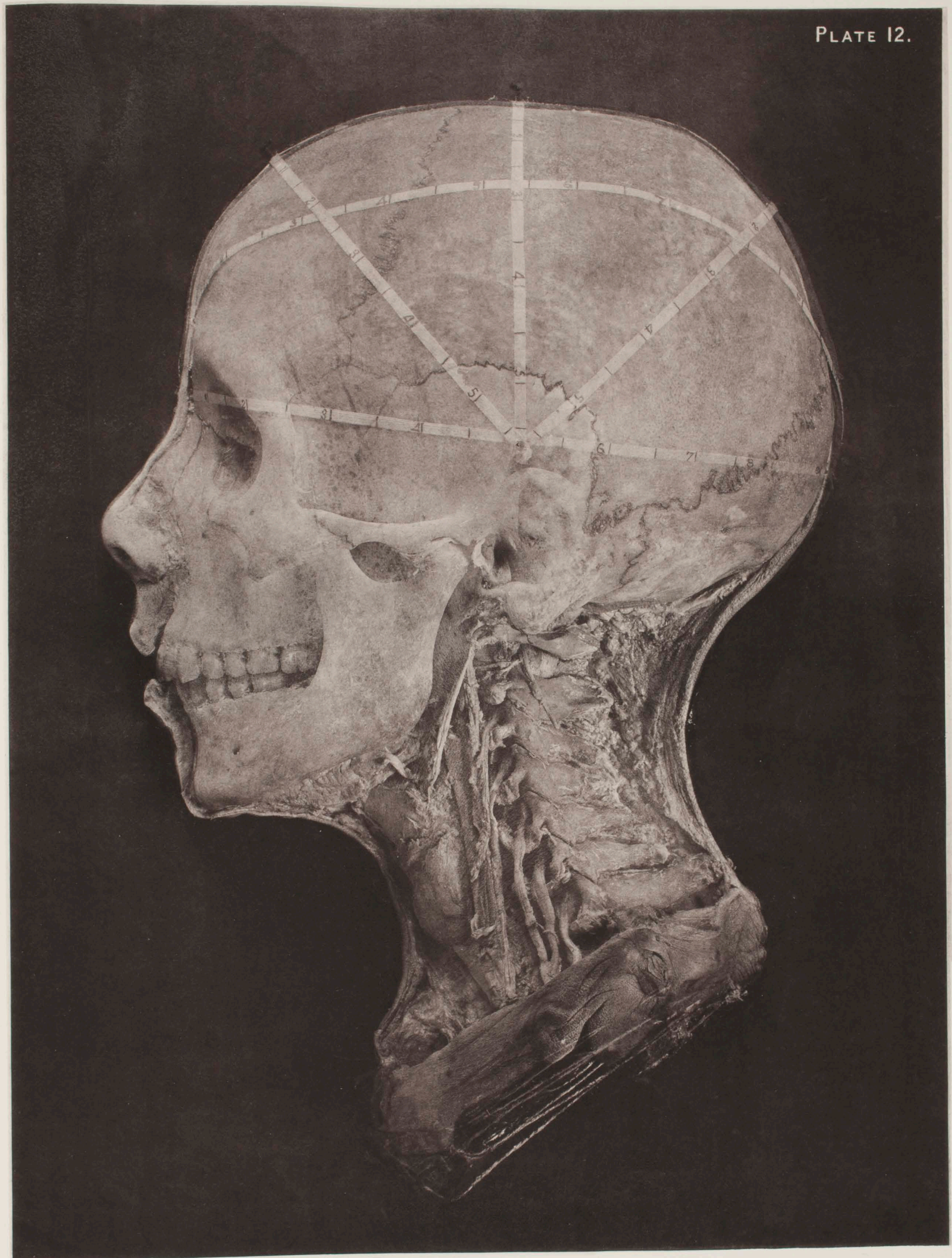












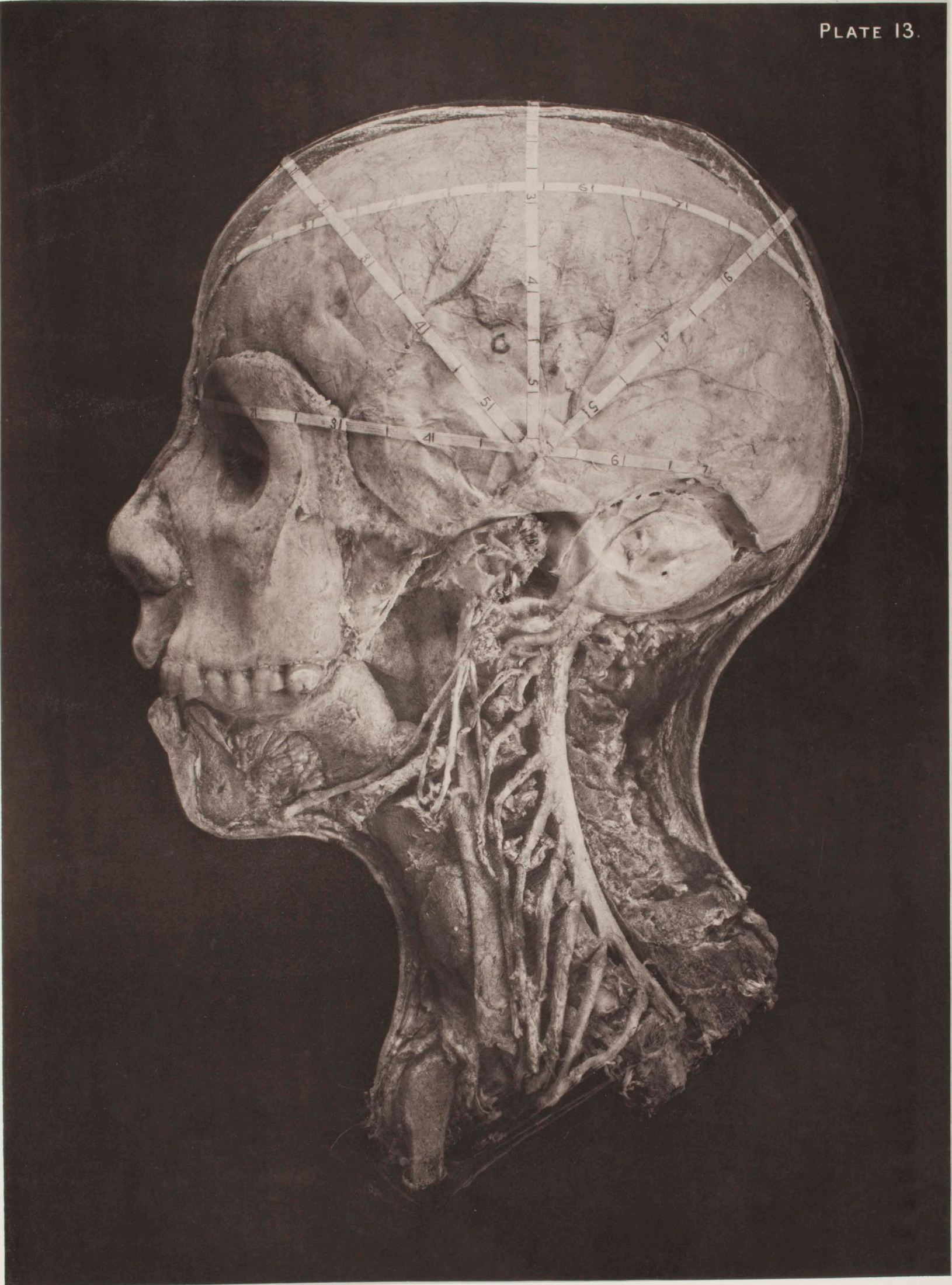









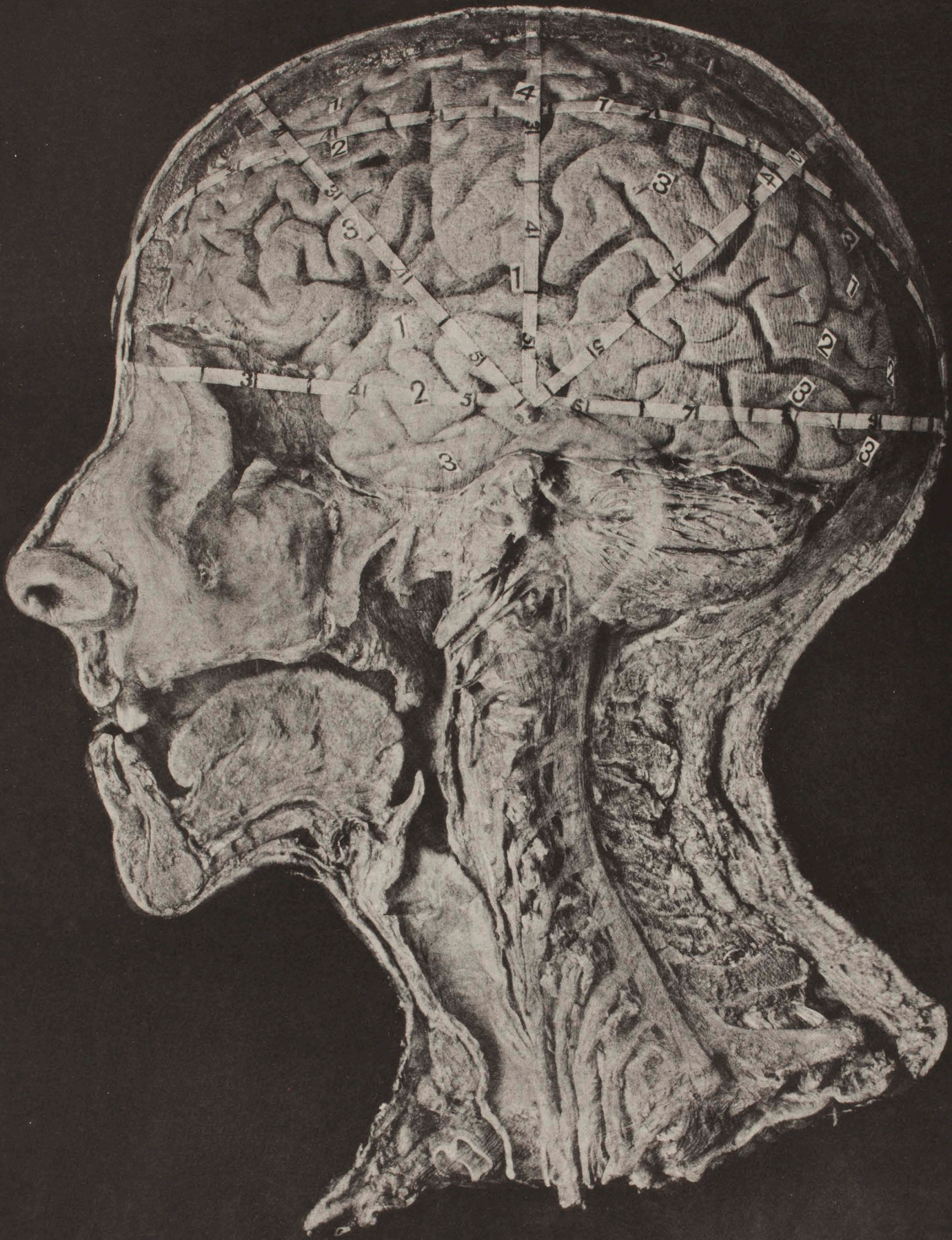











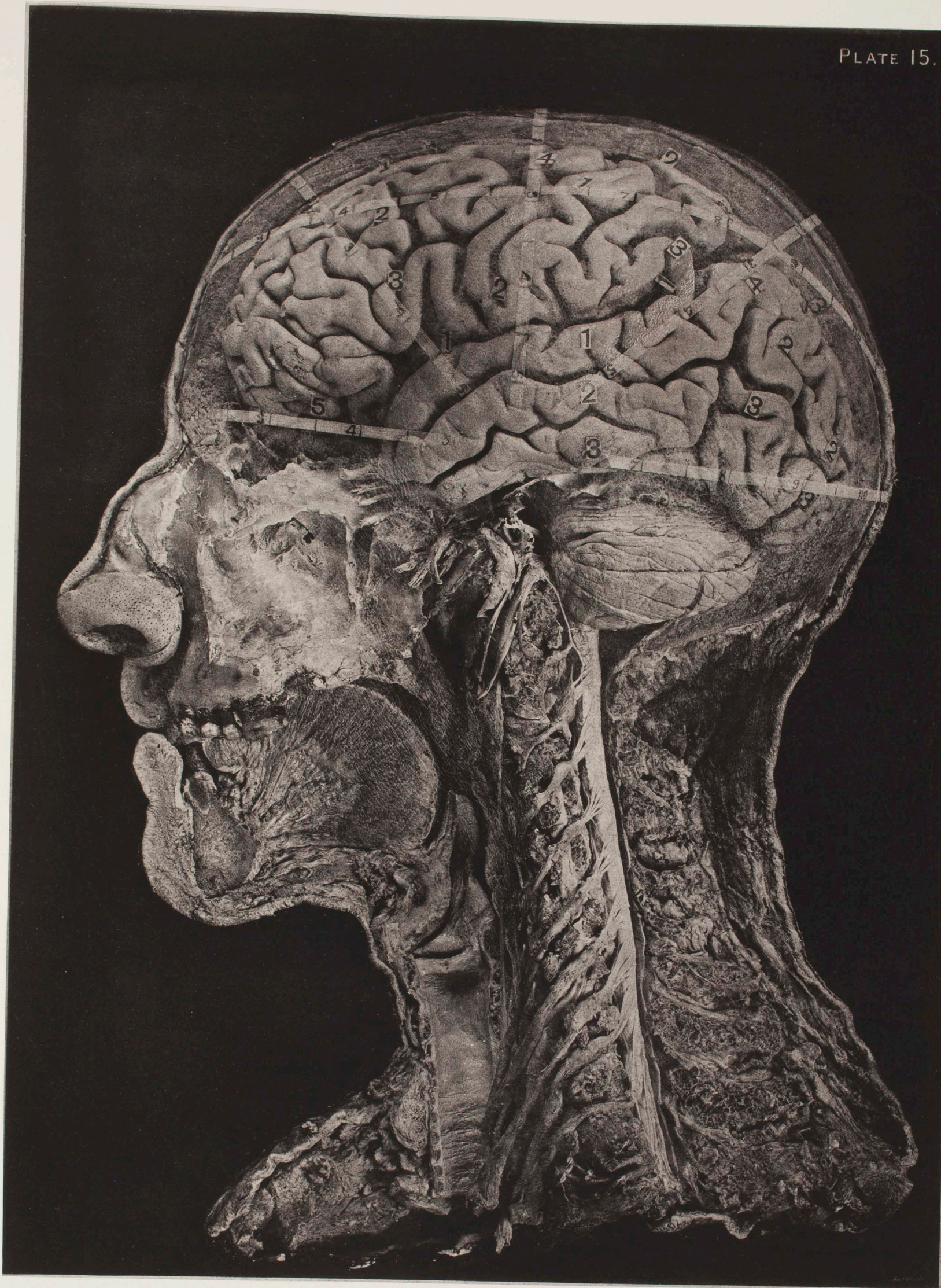


AUTOTYP.






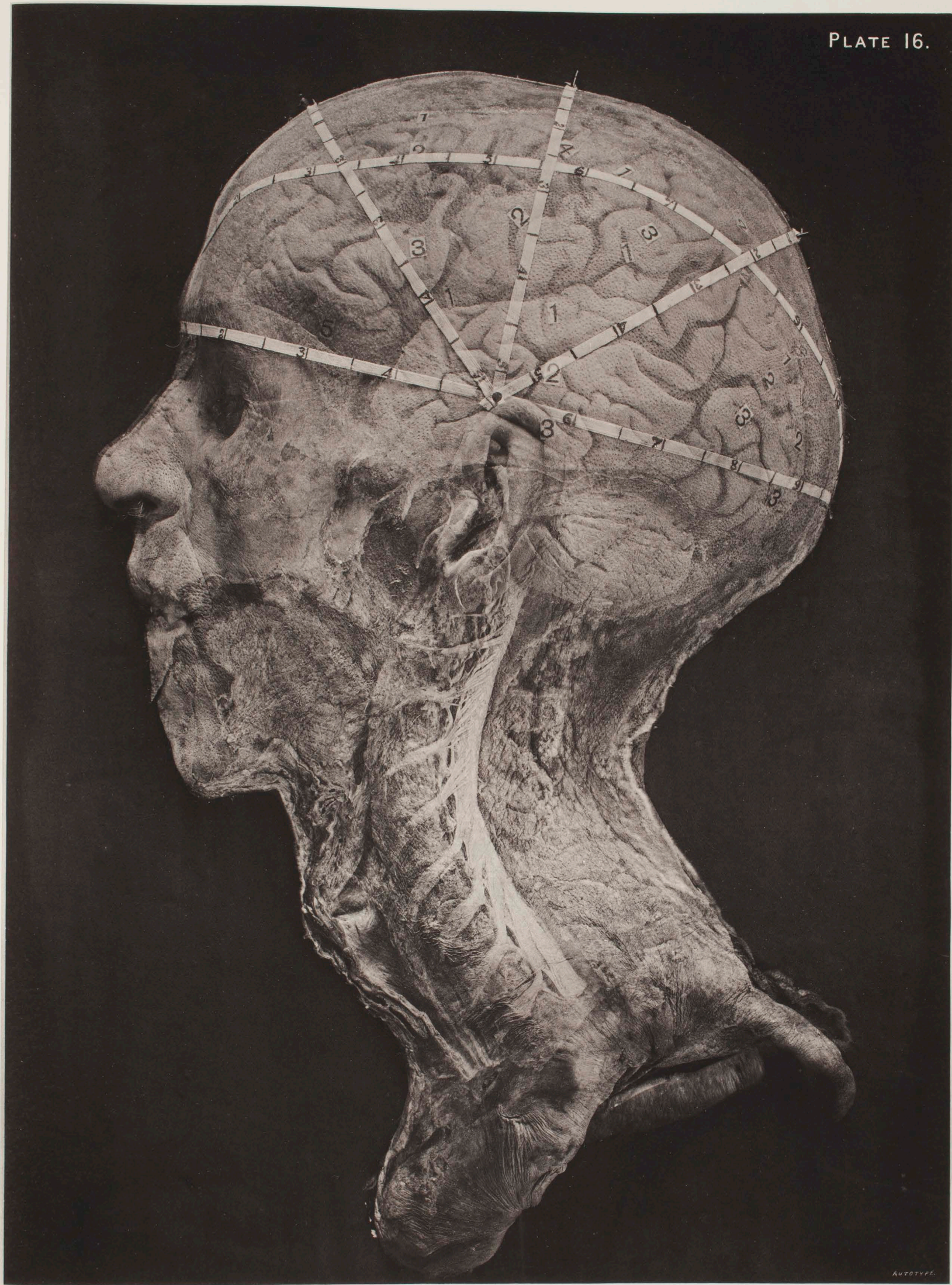








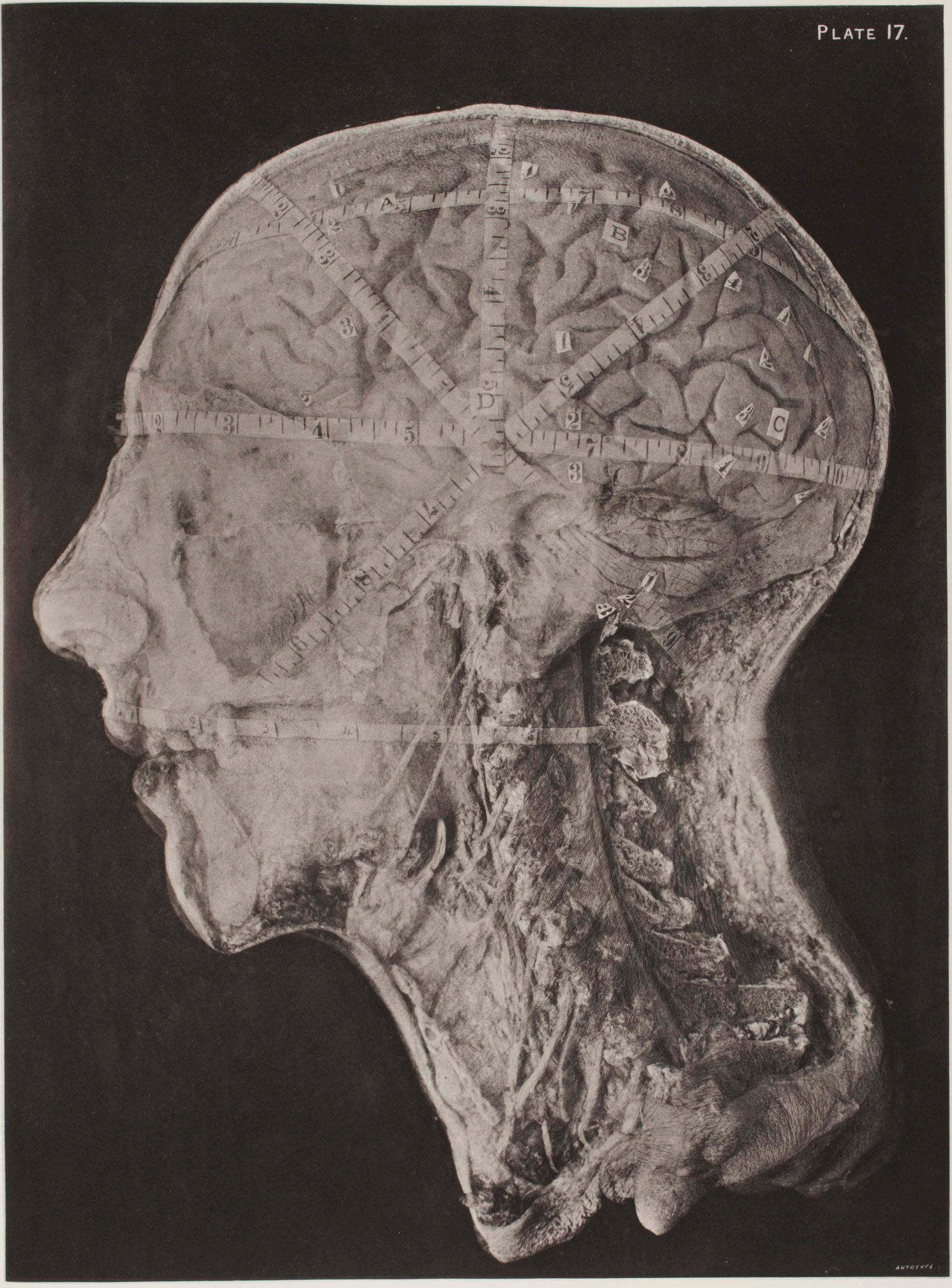















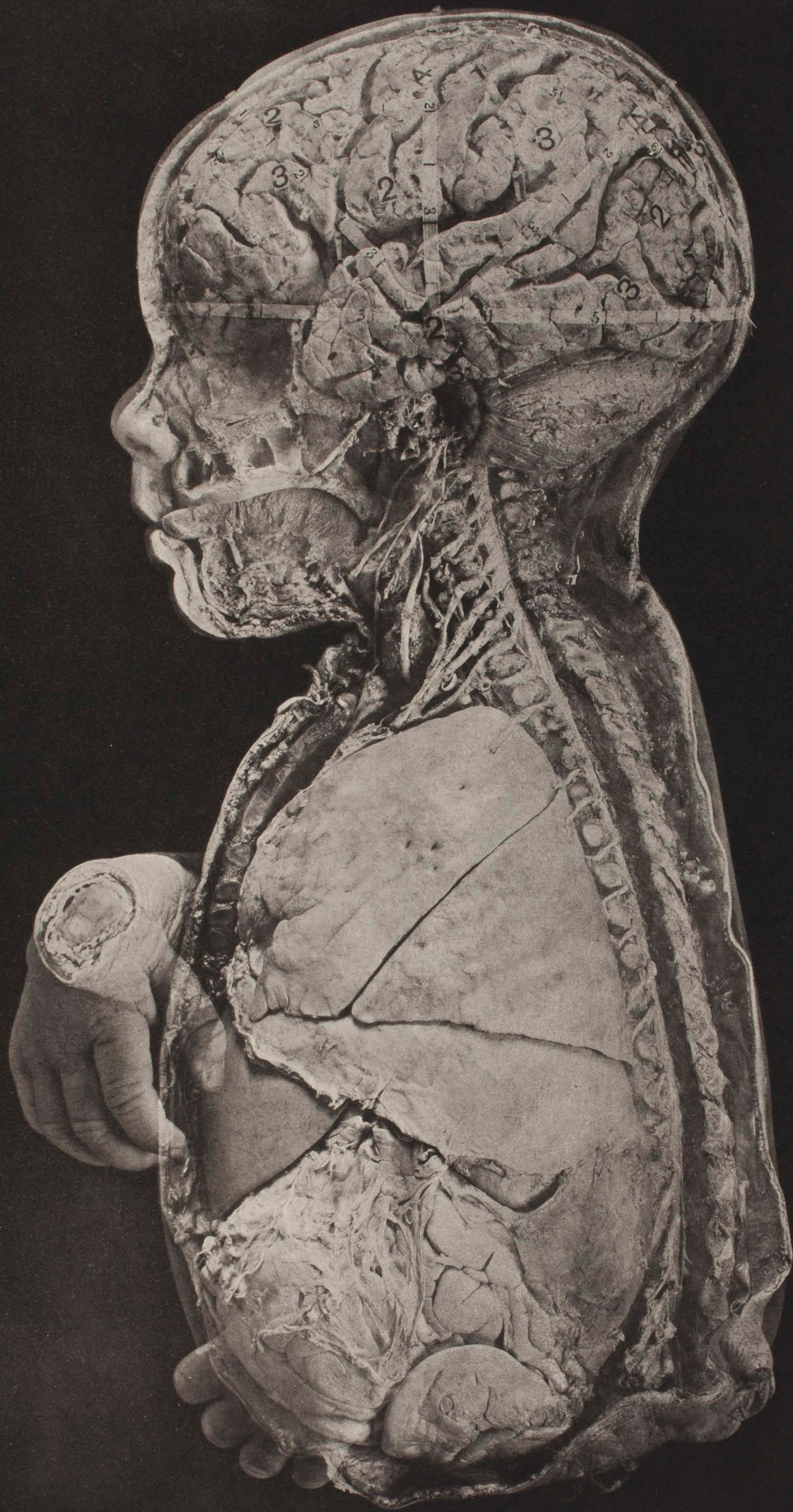











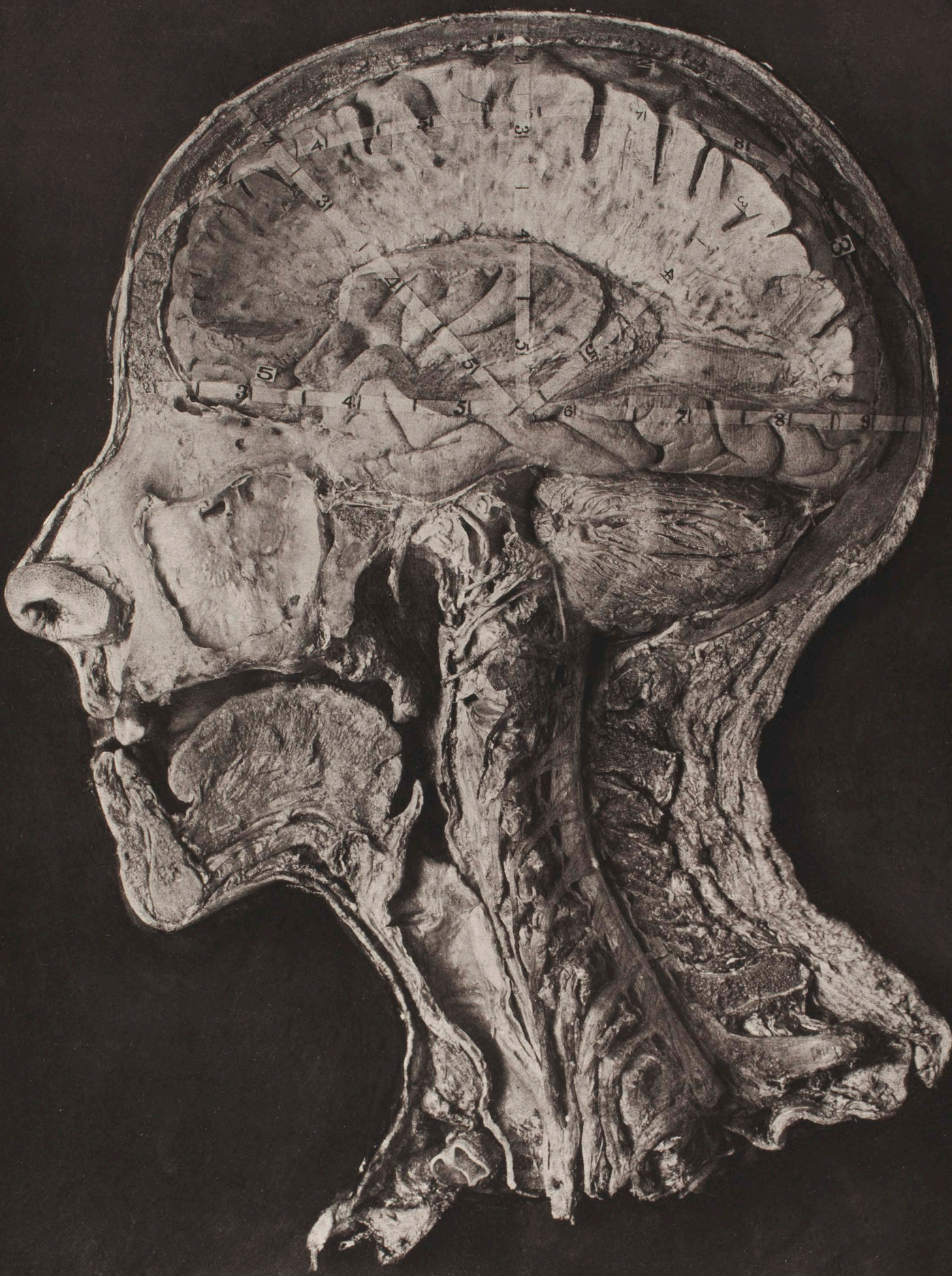









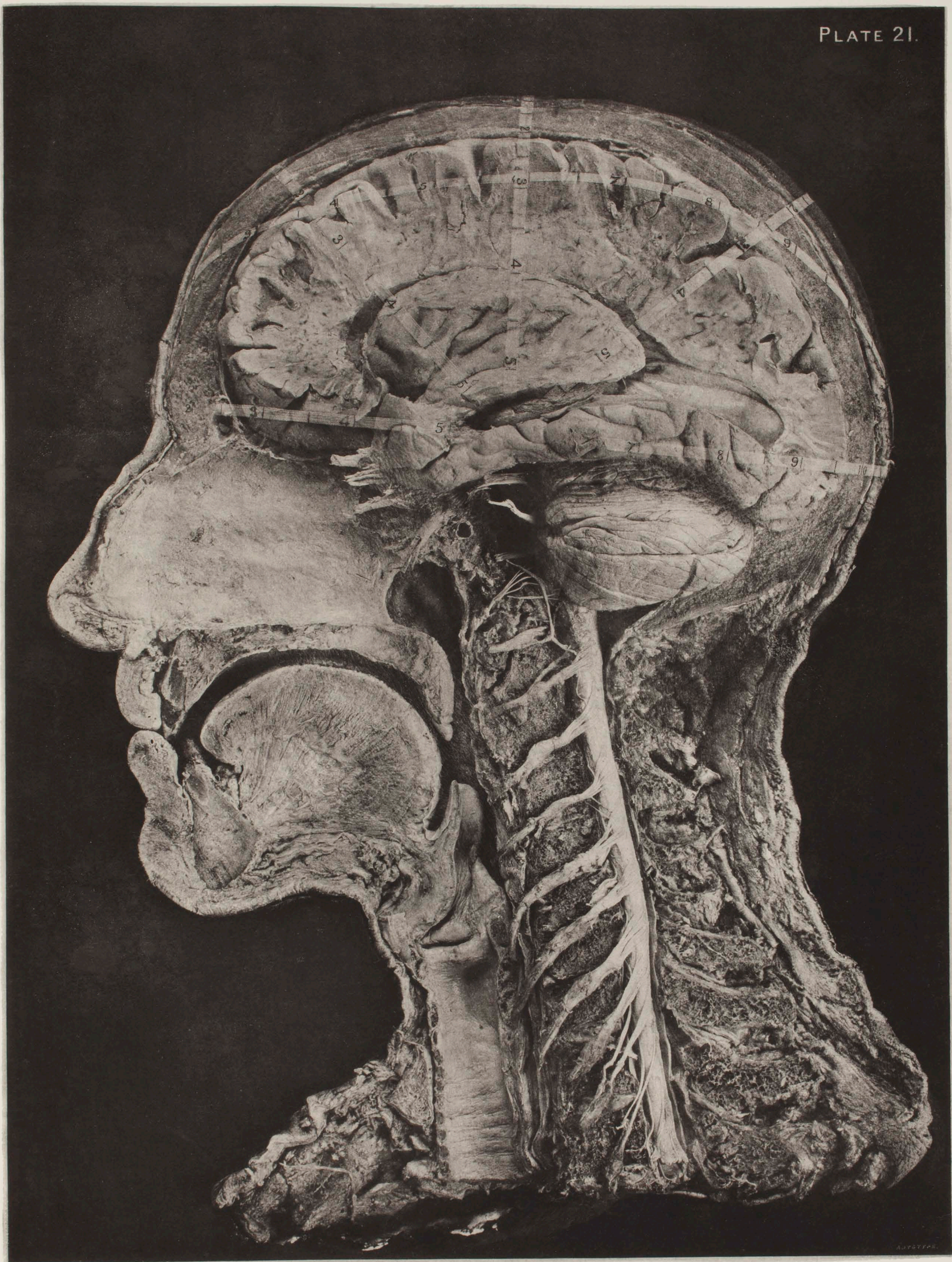






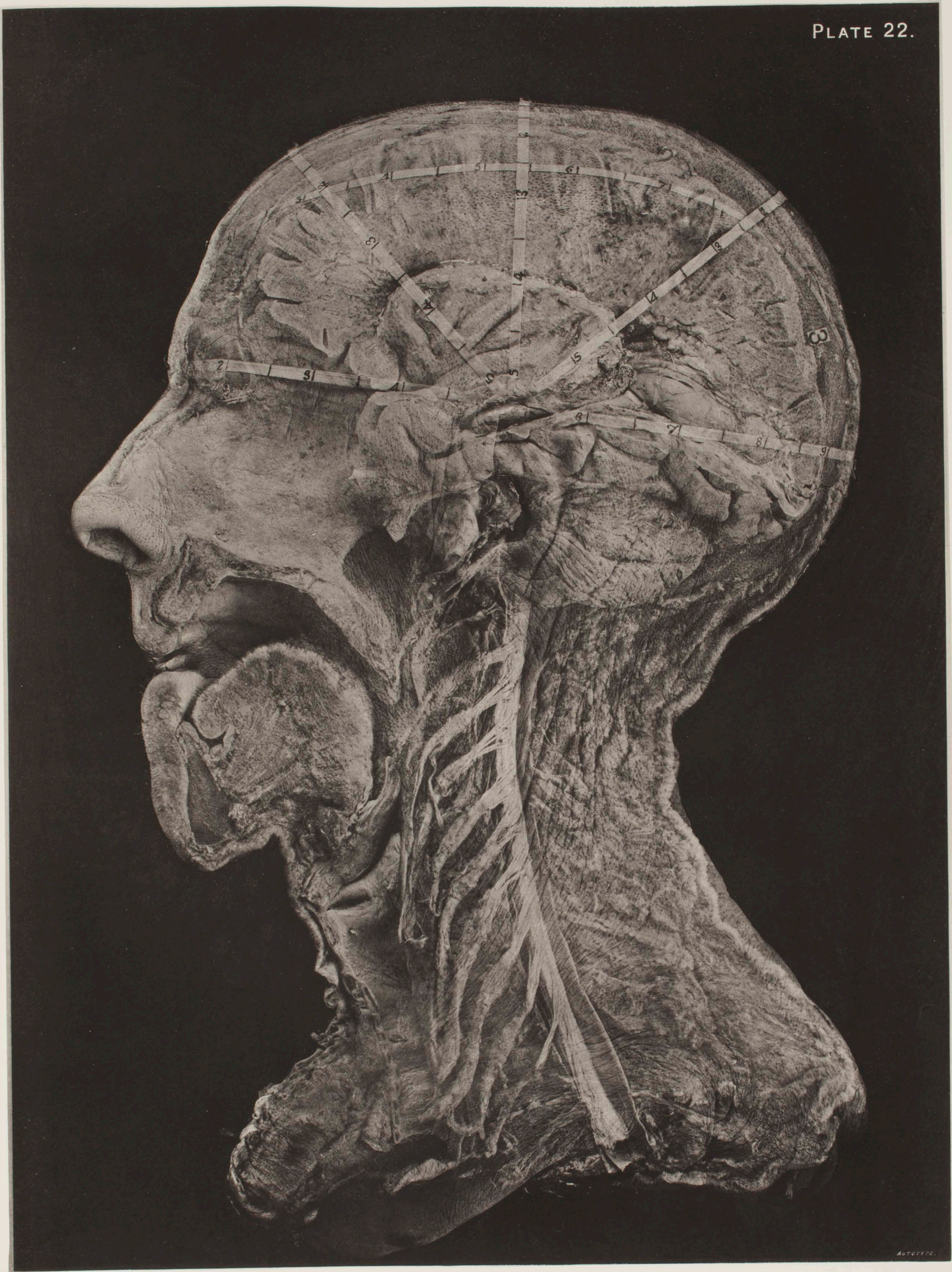






A. LEITCH.





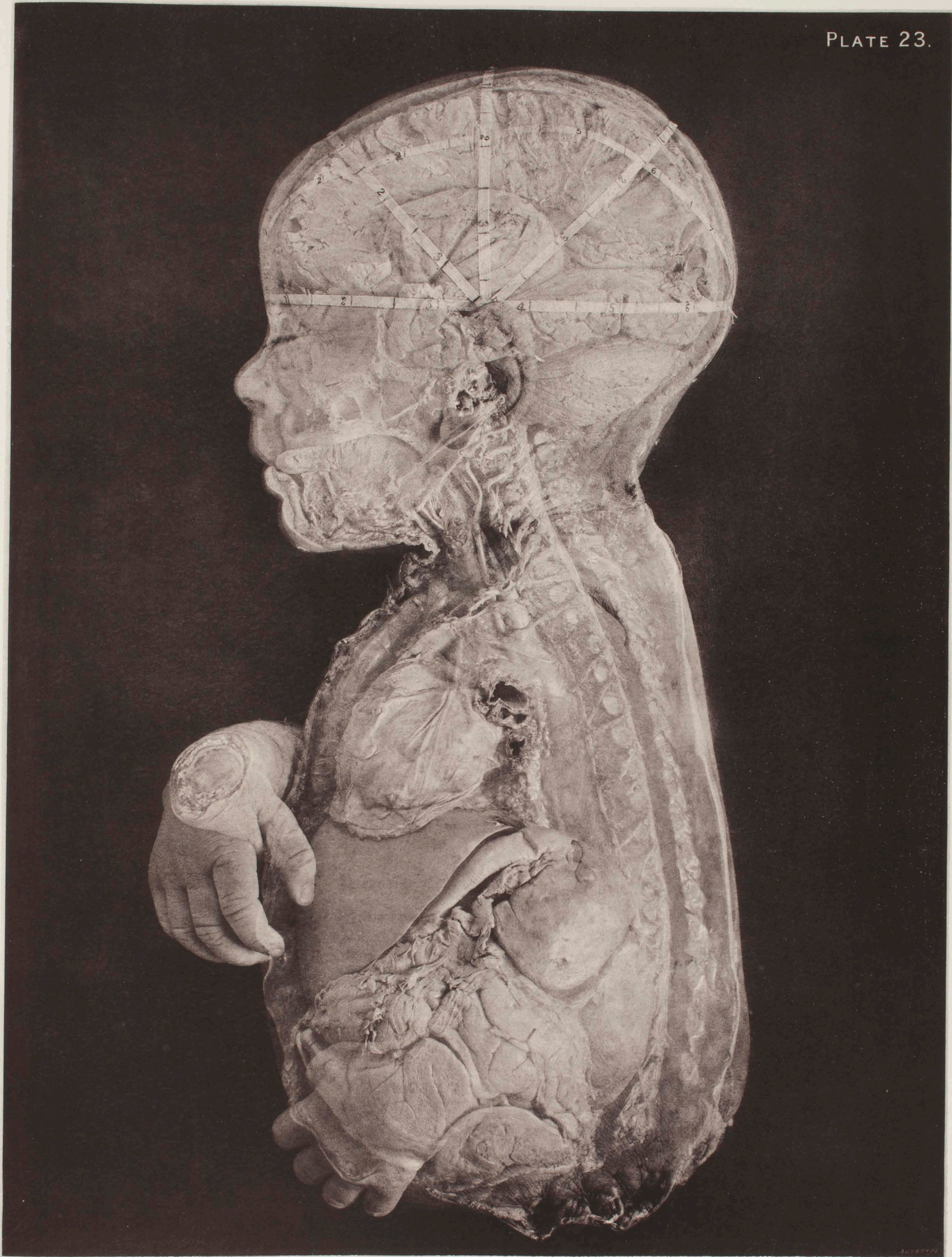









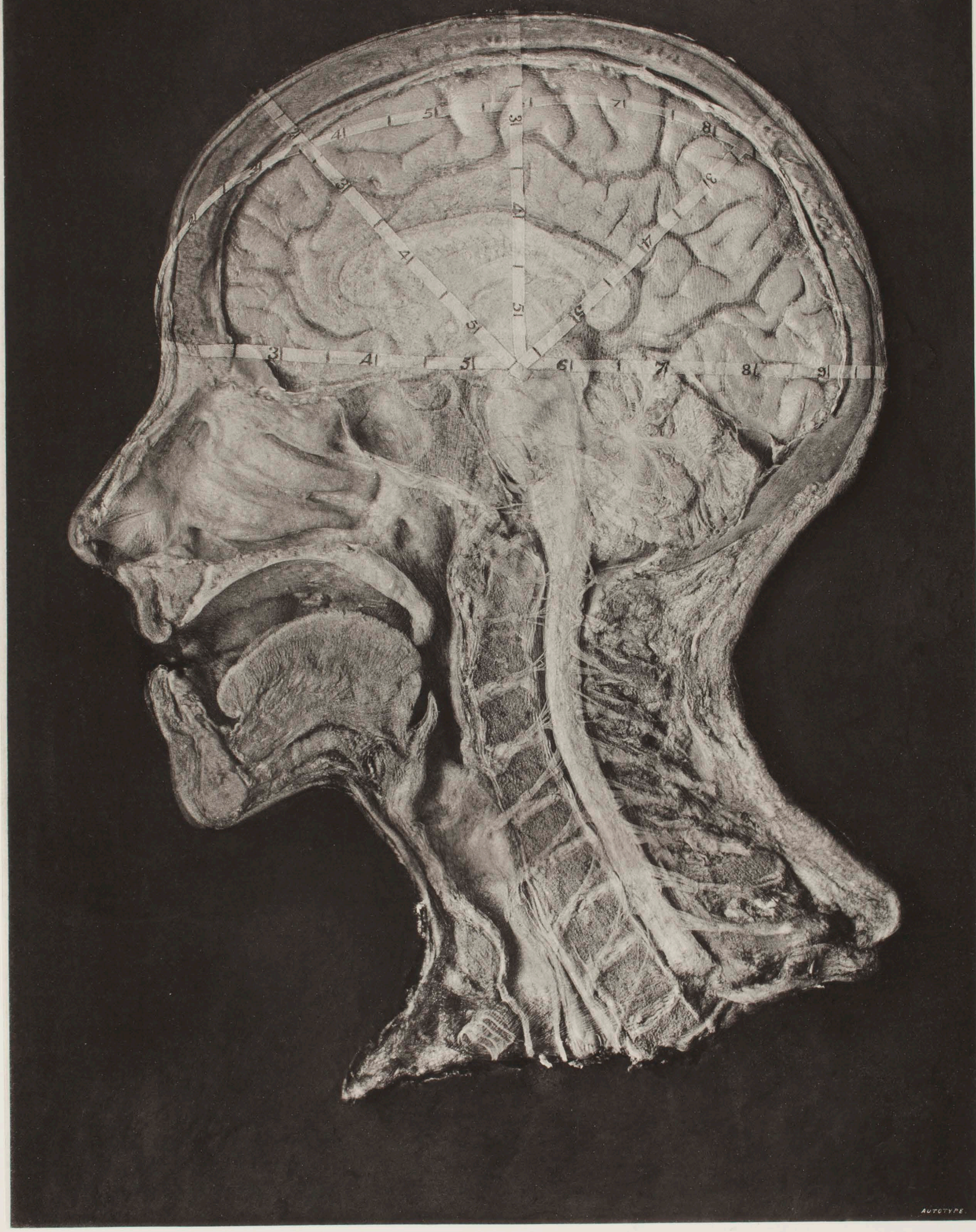











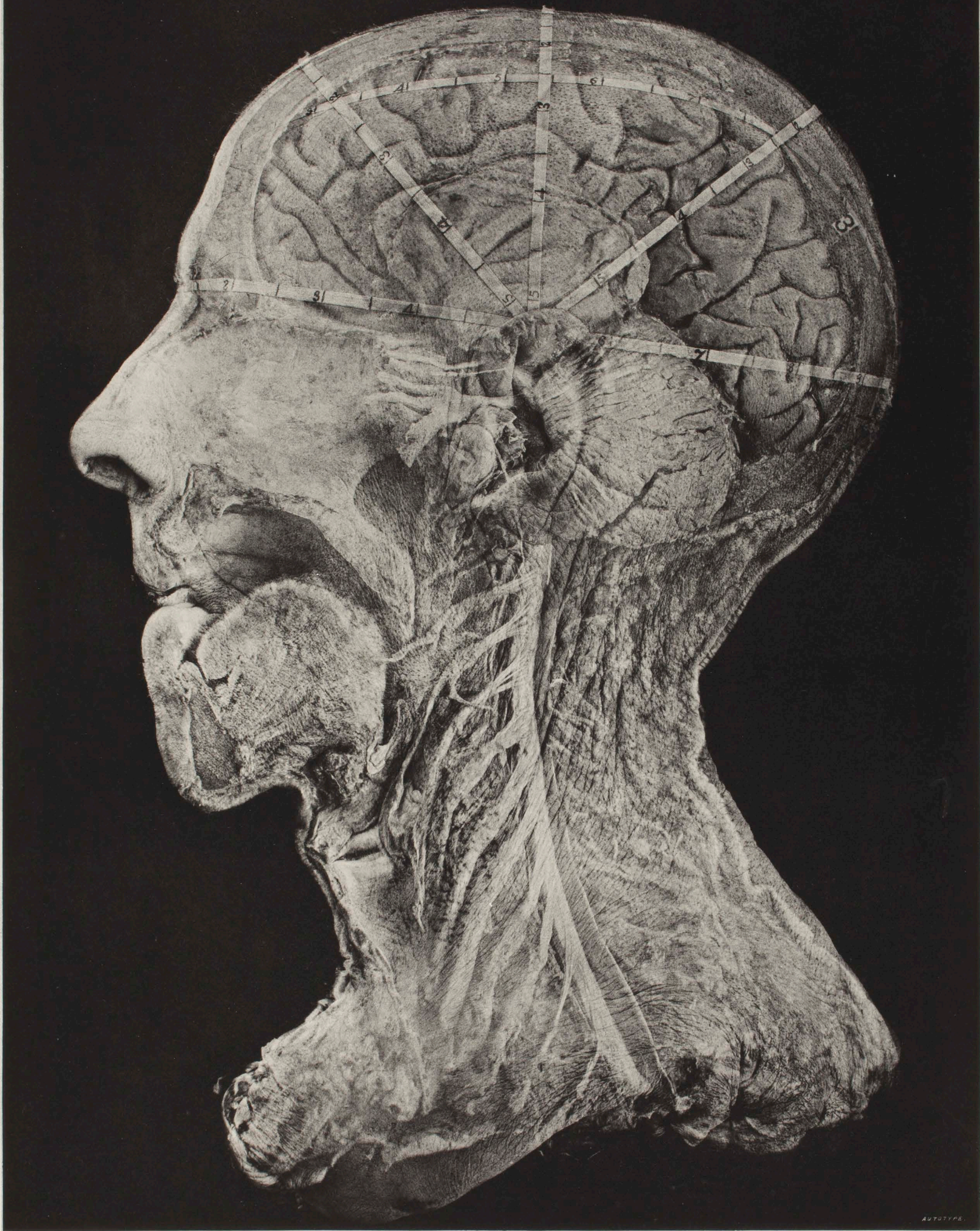

AUTOTYPE.

















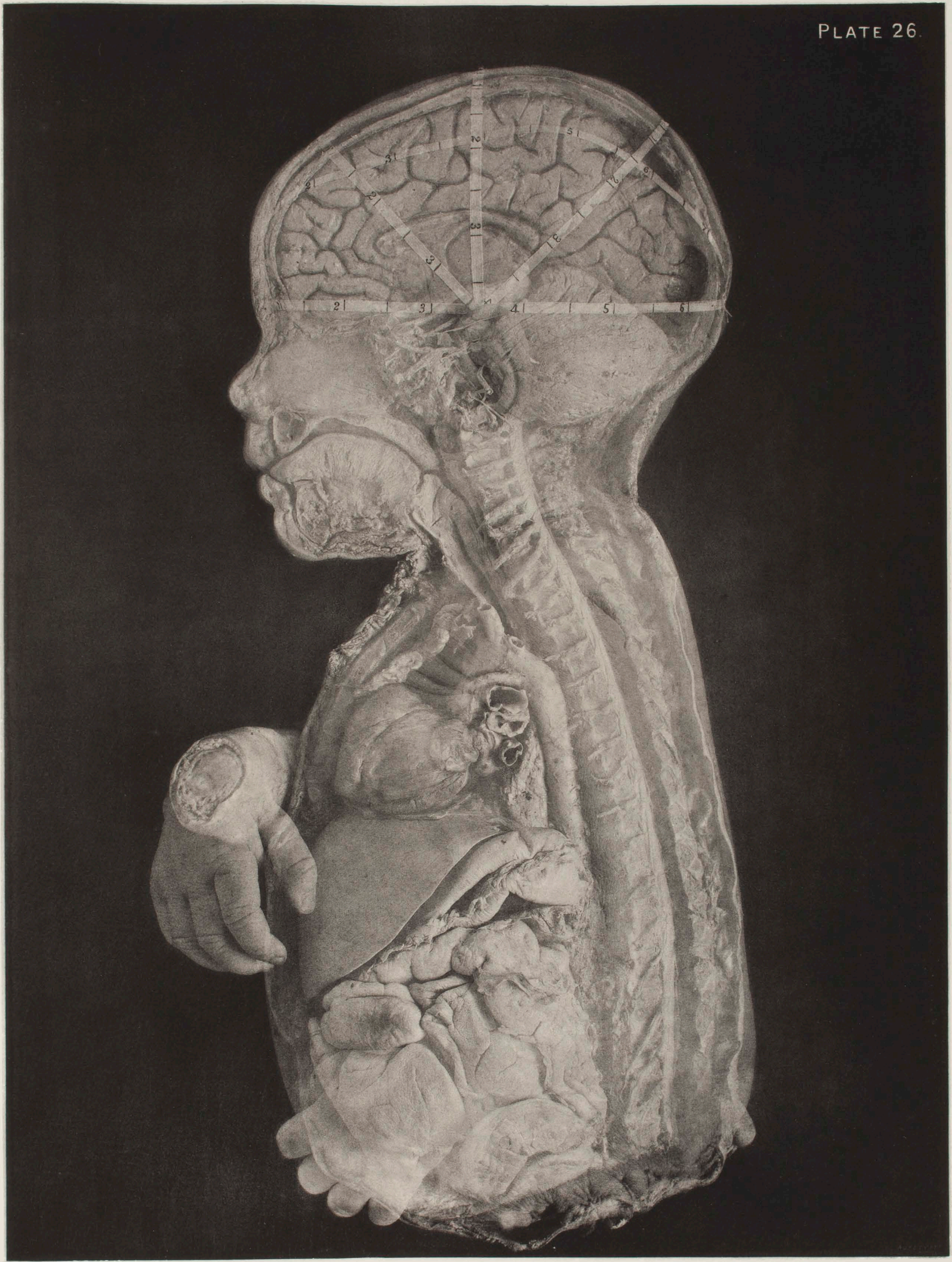









FIG. 1.

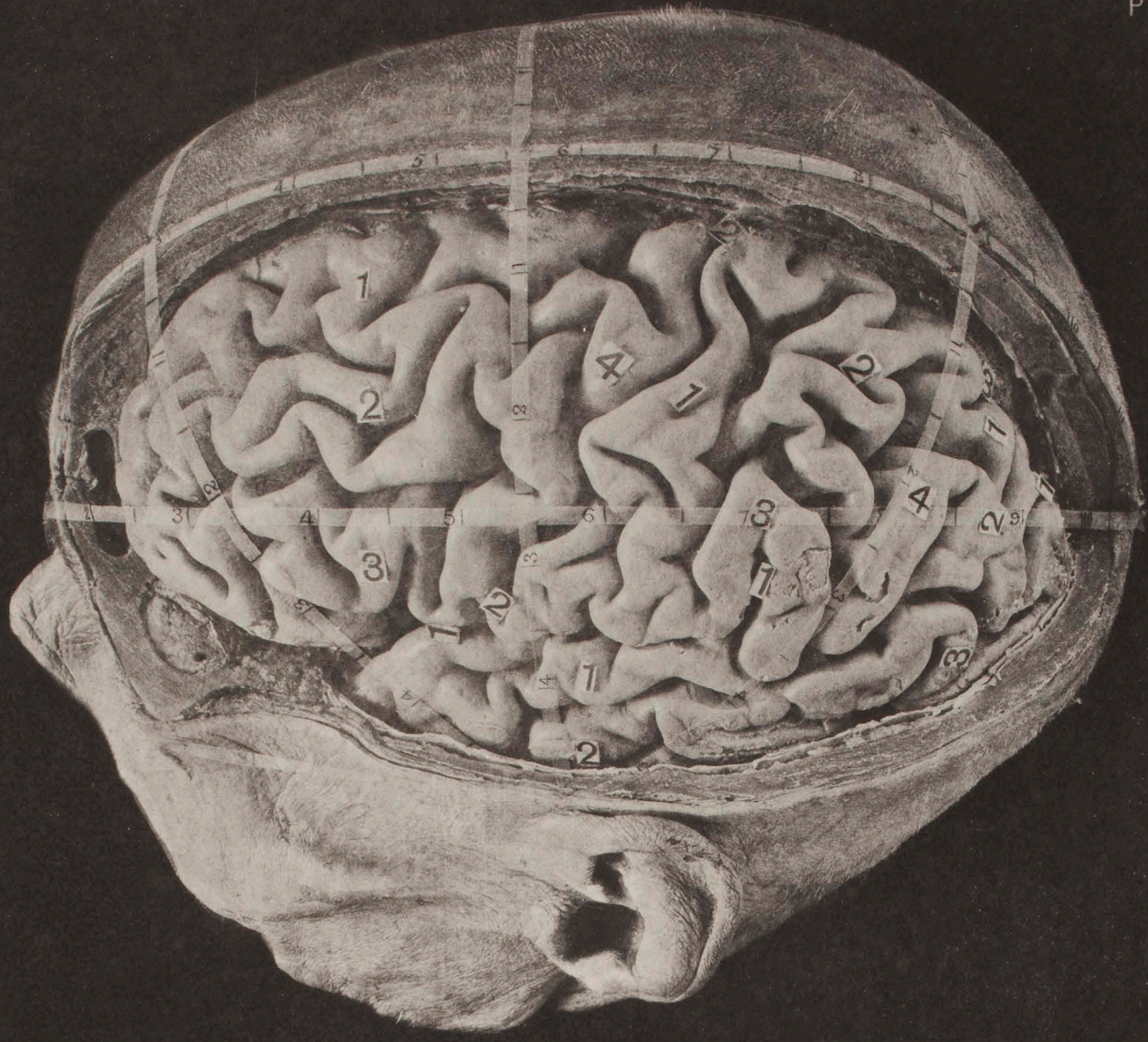
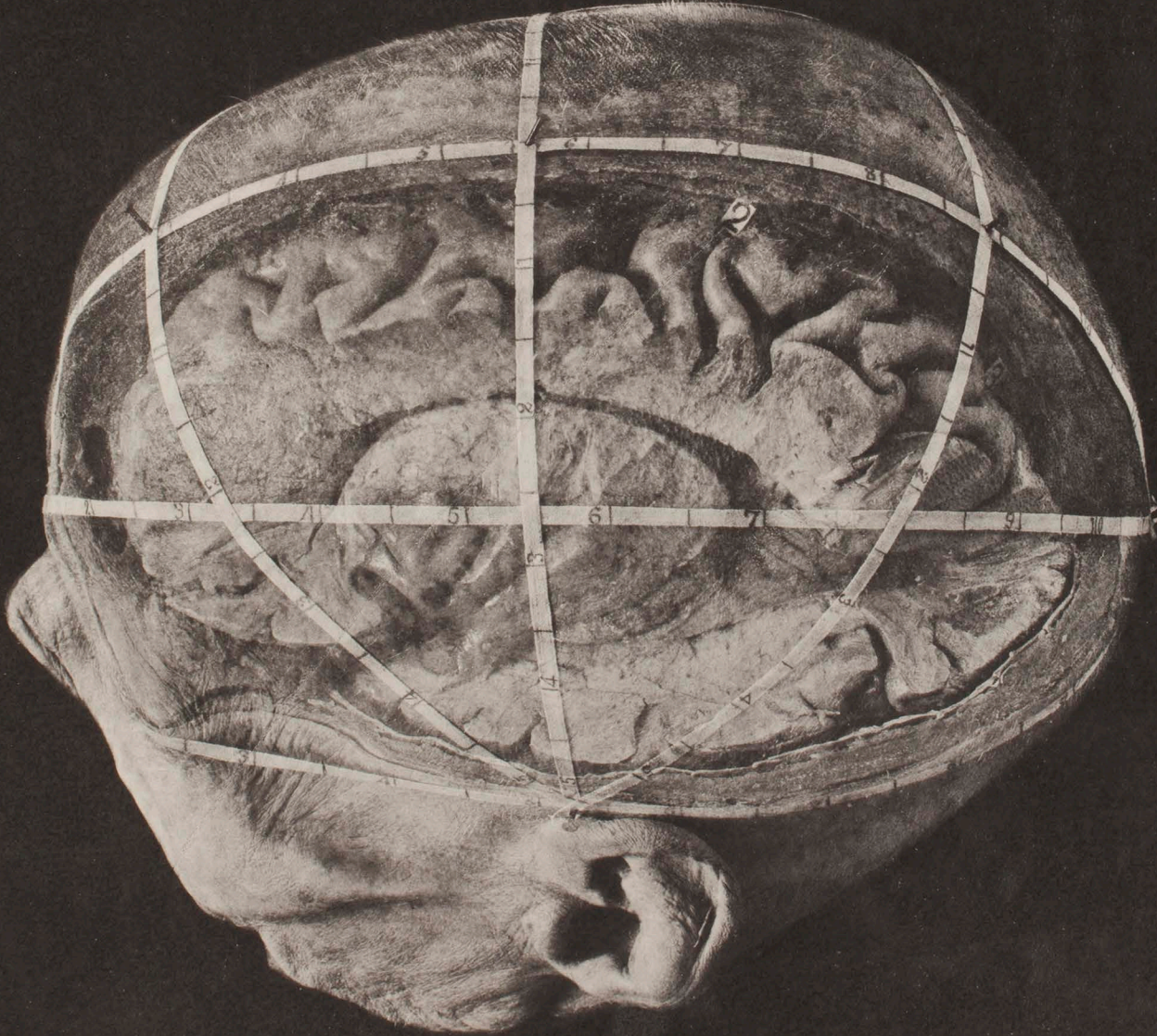


FIG. 2.






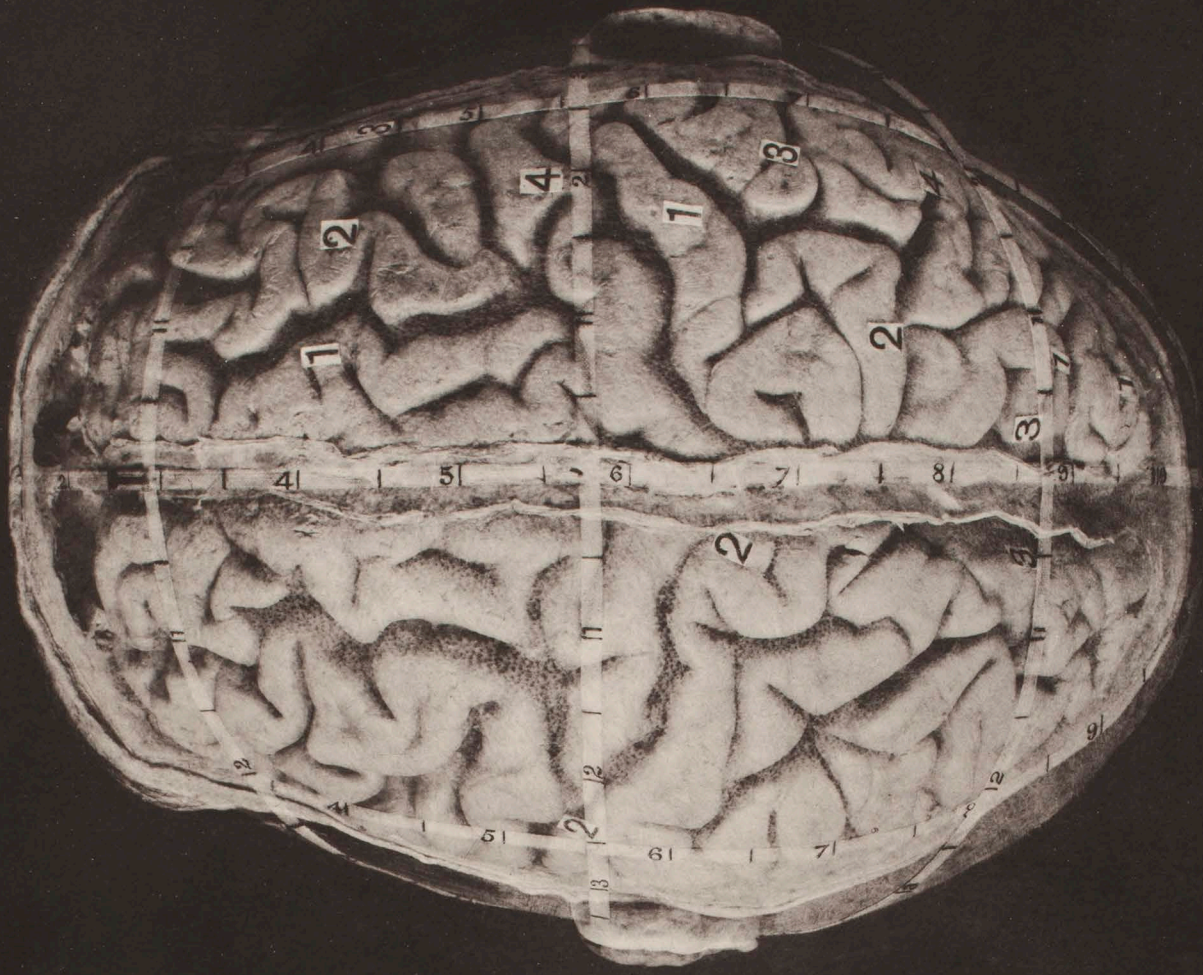


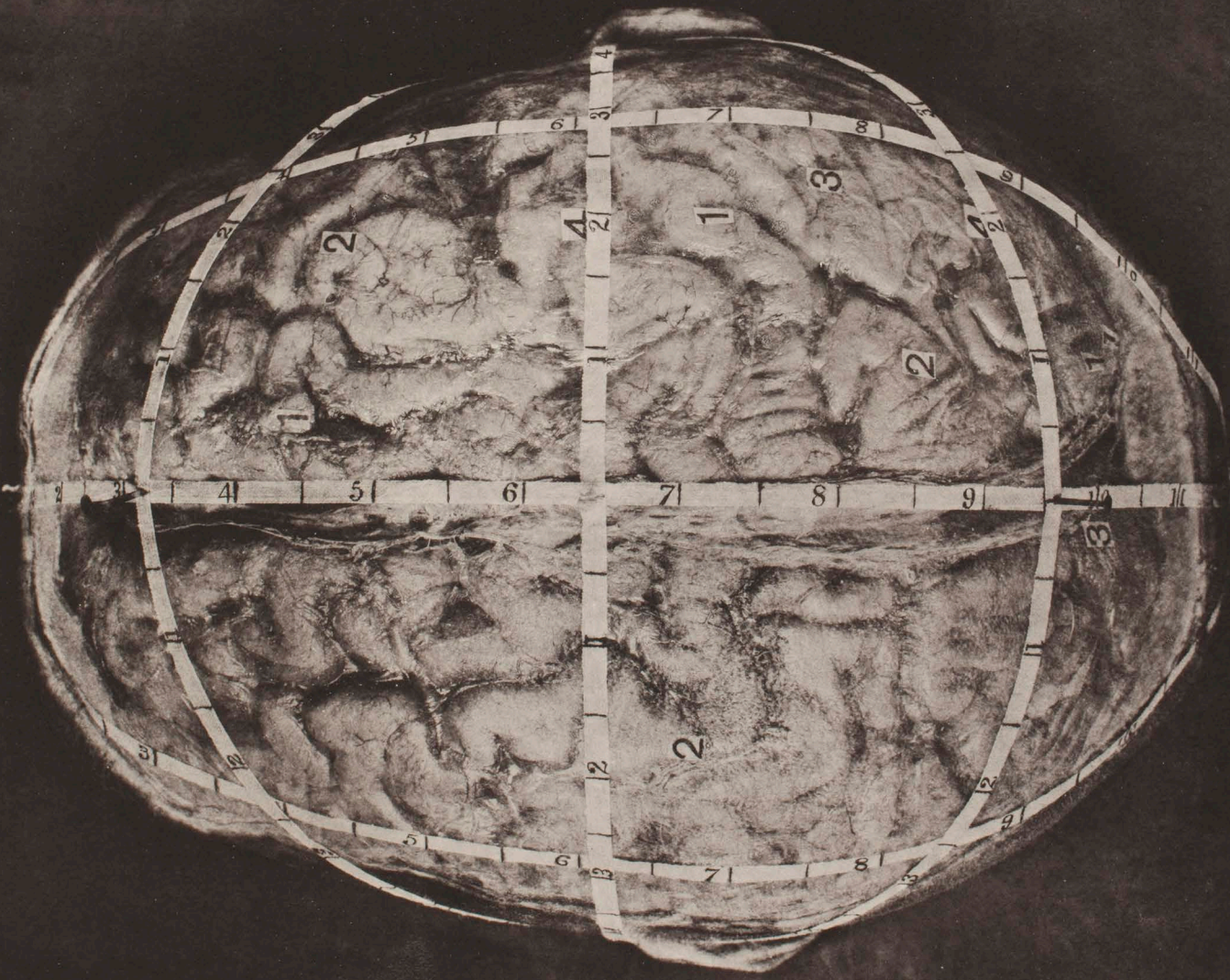


FIG. 2.



AUTOTYPE

FIG. 1.










FIG. 2.

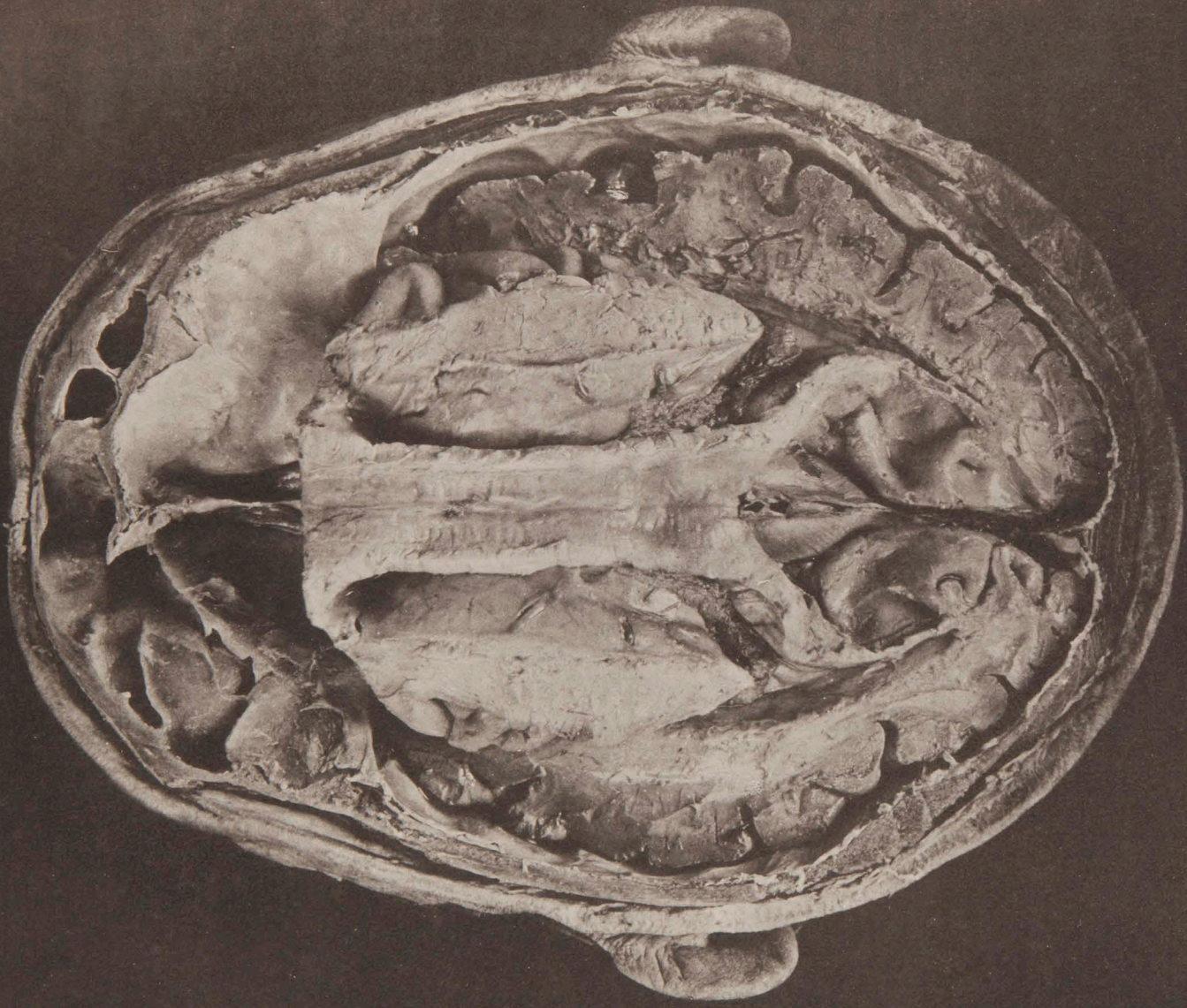
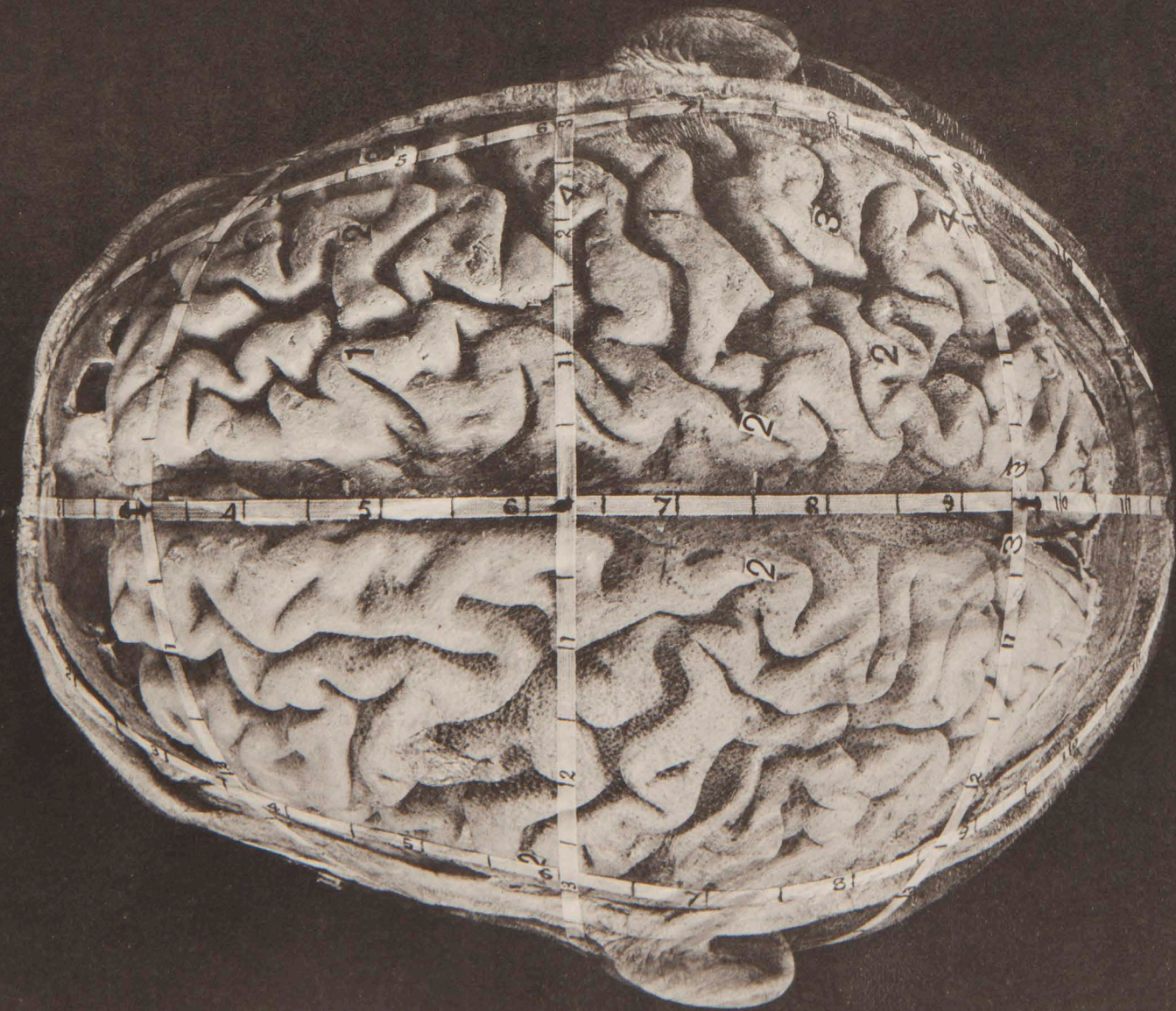


FIG. 1.



ARTIST'S








FIG. 2.

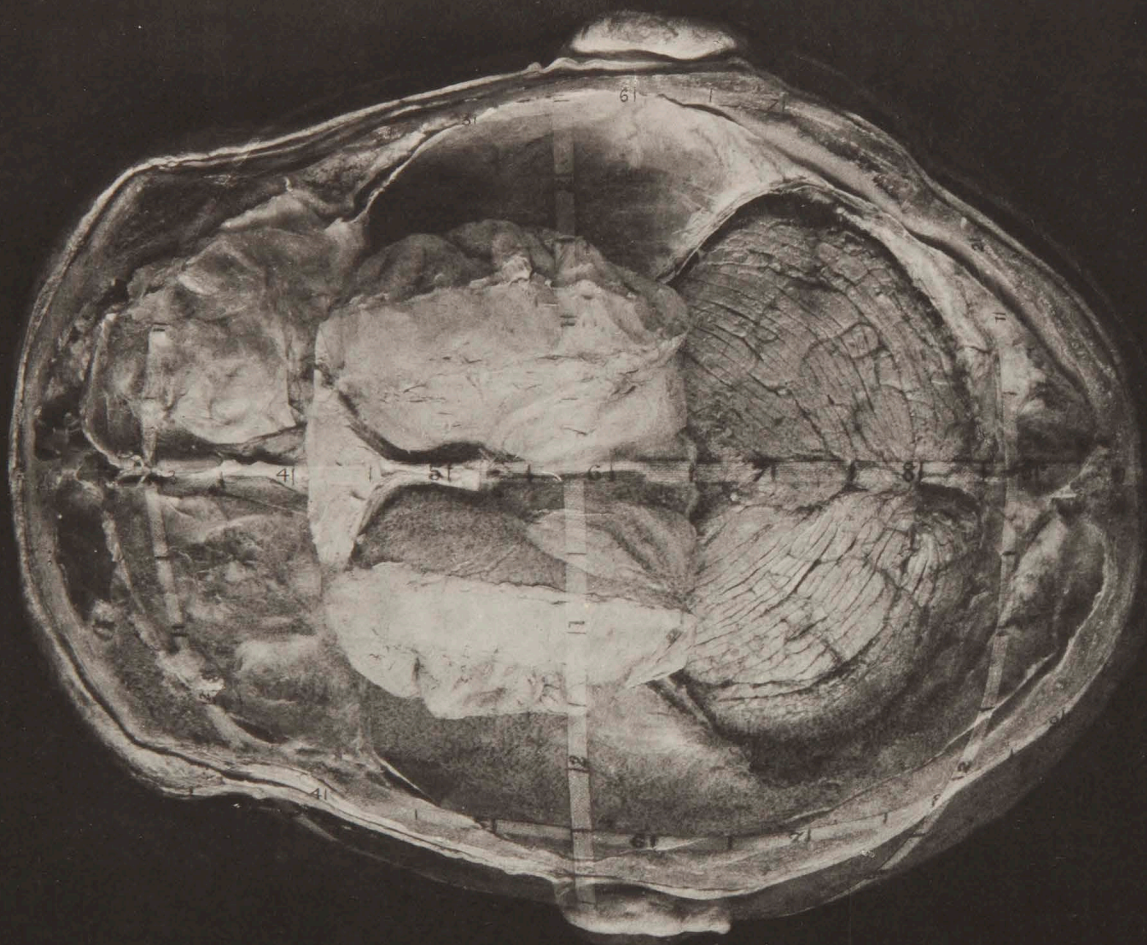


FIG. 1.

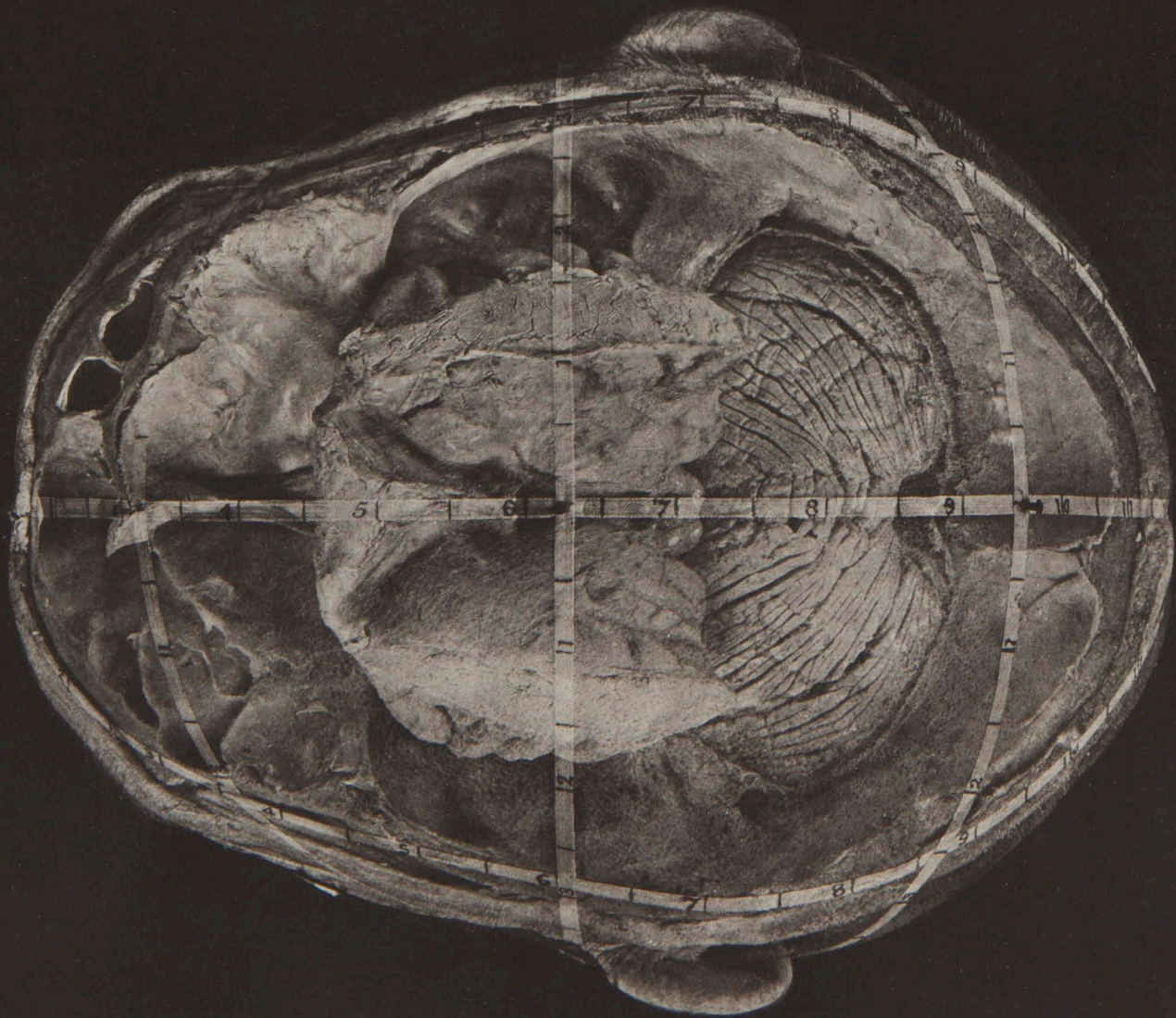








PLATE 31.

FIG 3.

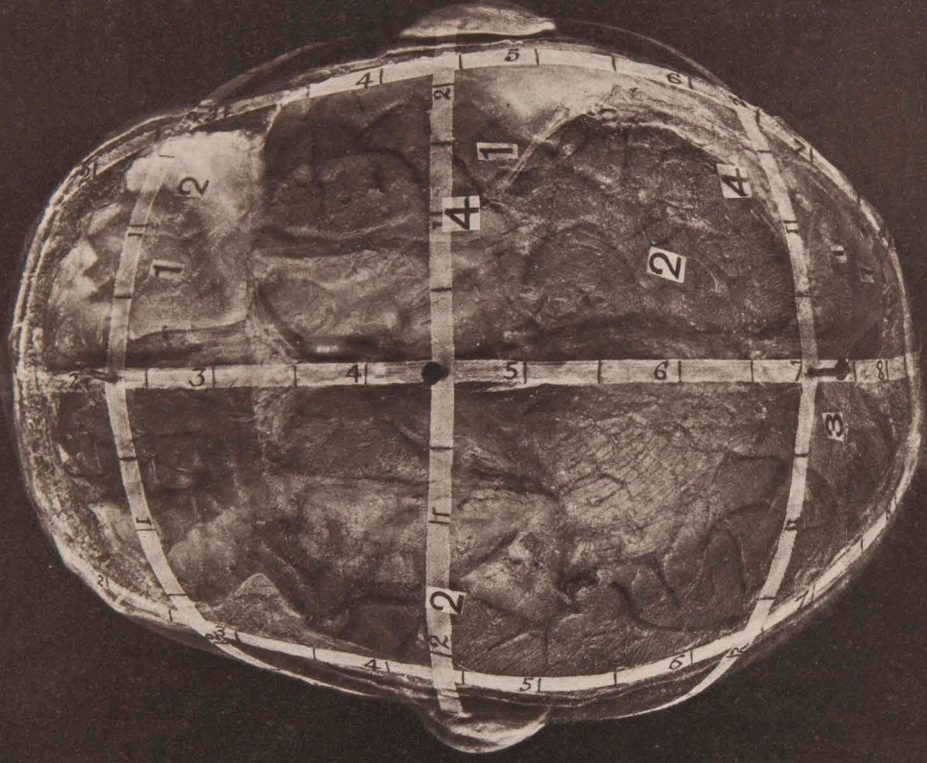


FIG 2.

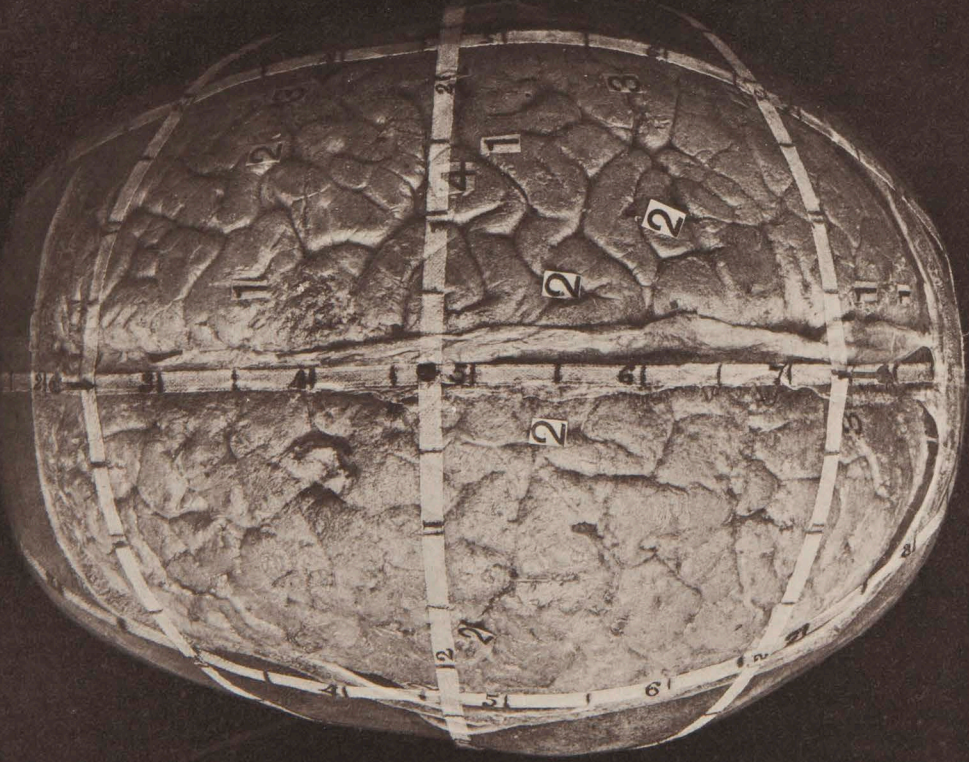
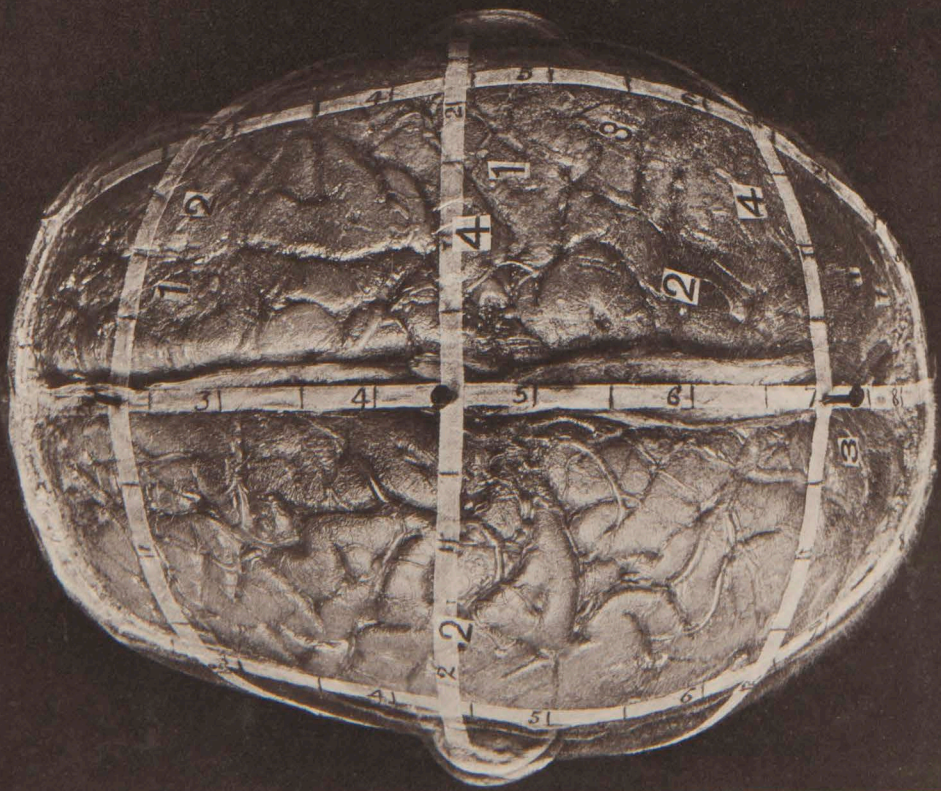


FIG 1.









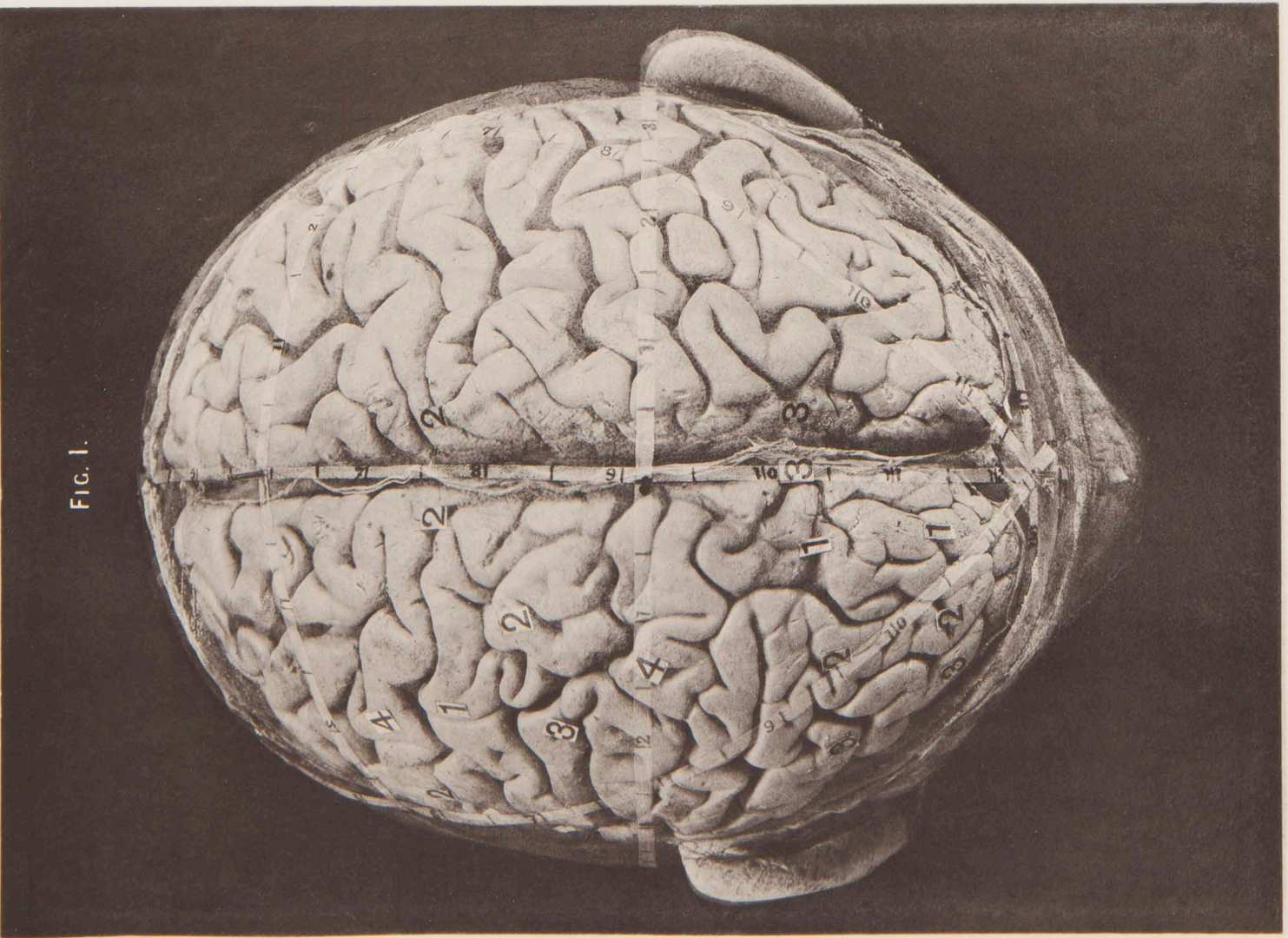


FIG. 1.

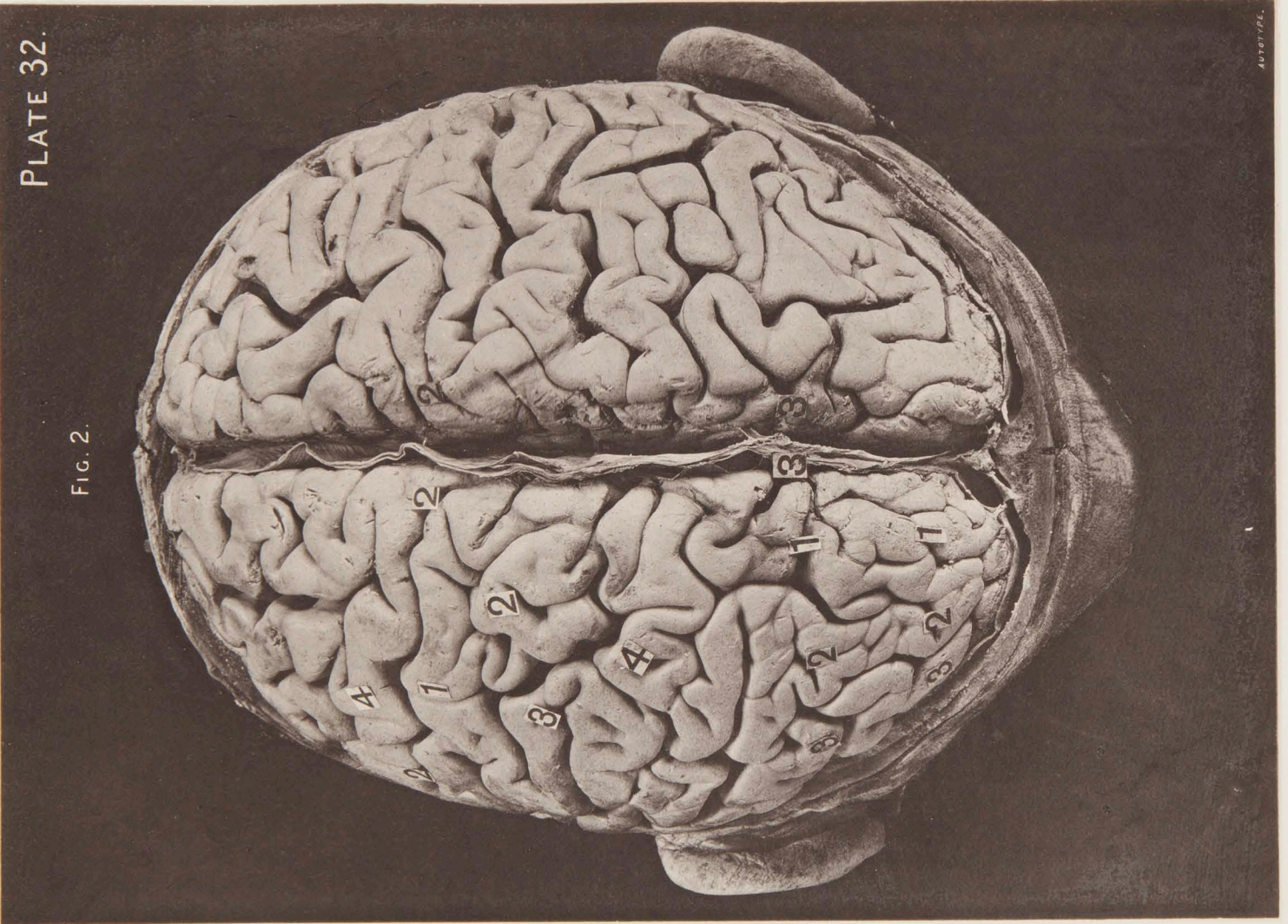
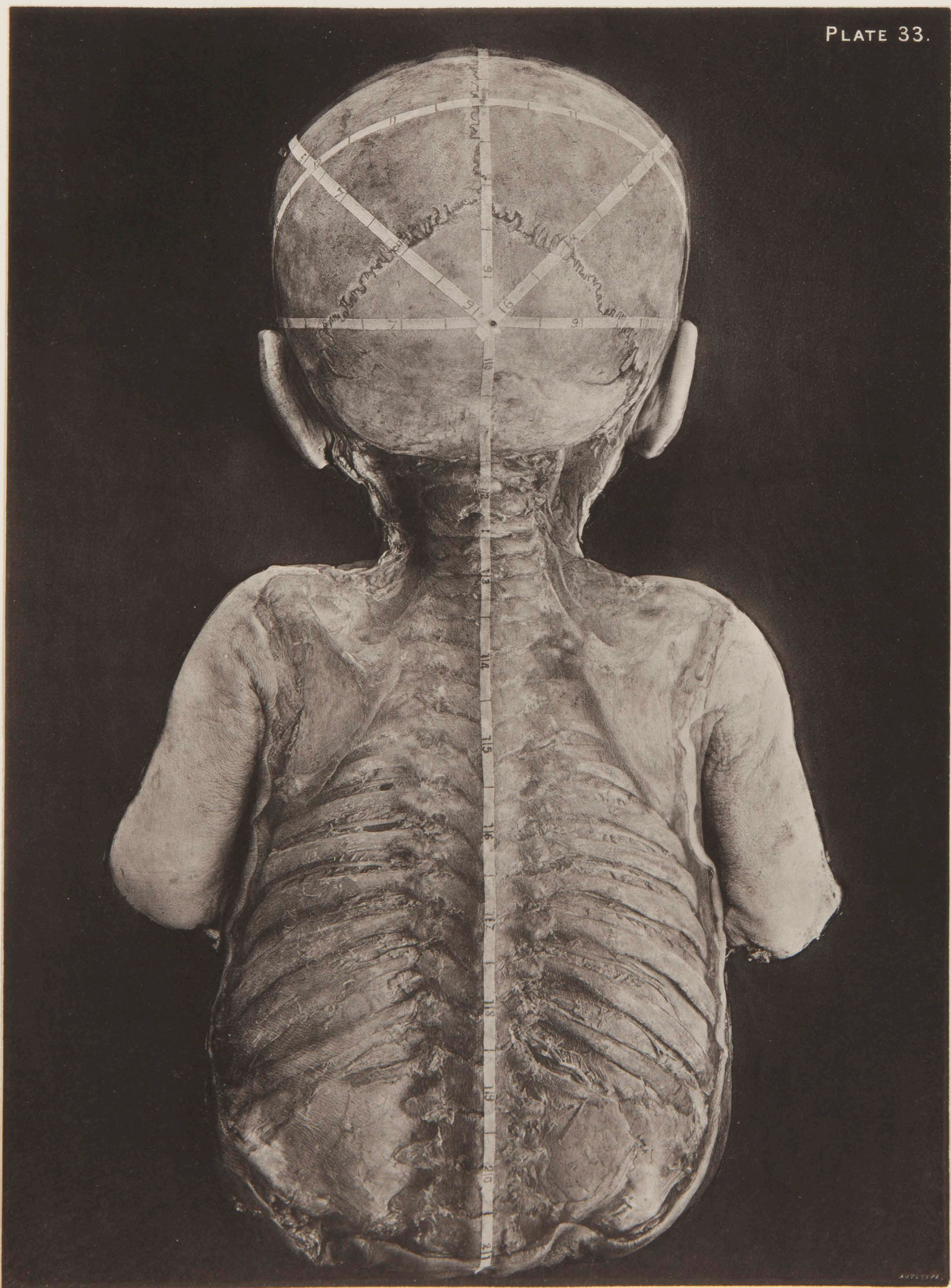


FIG. 2.






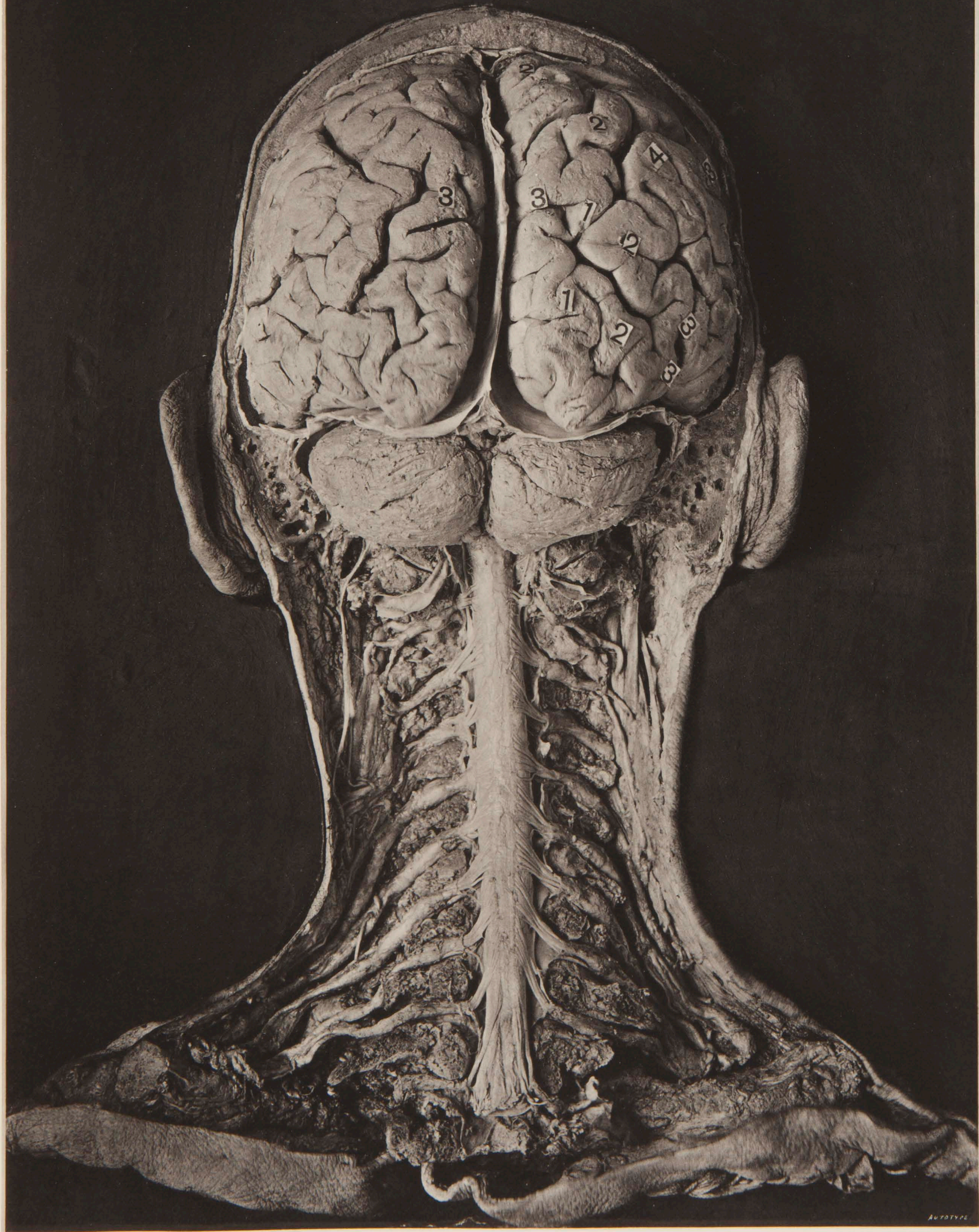









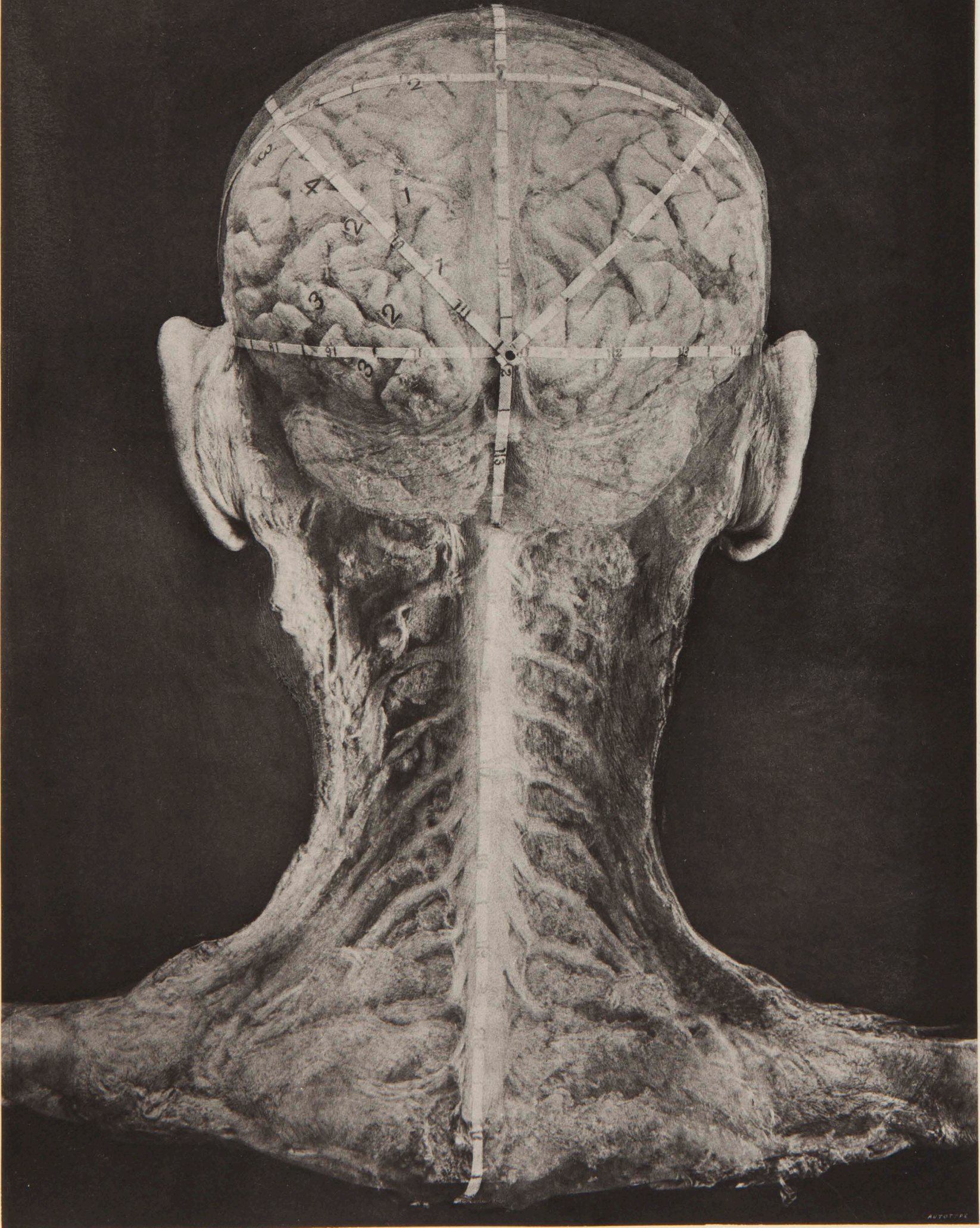









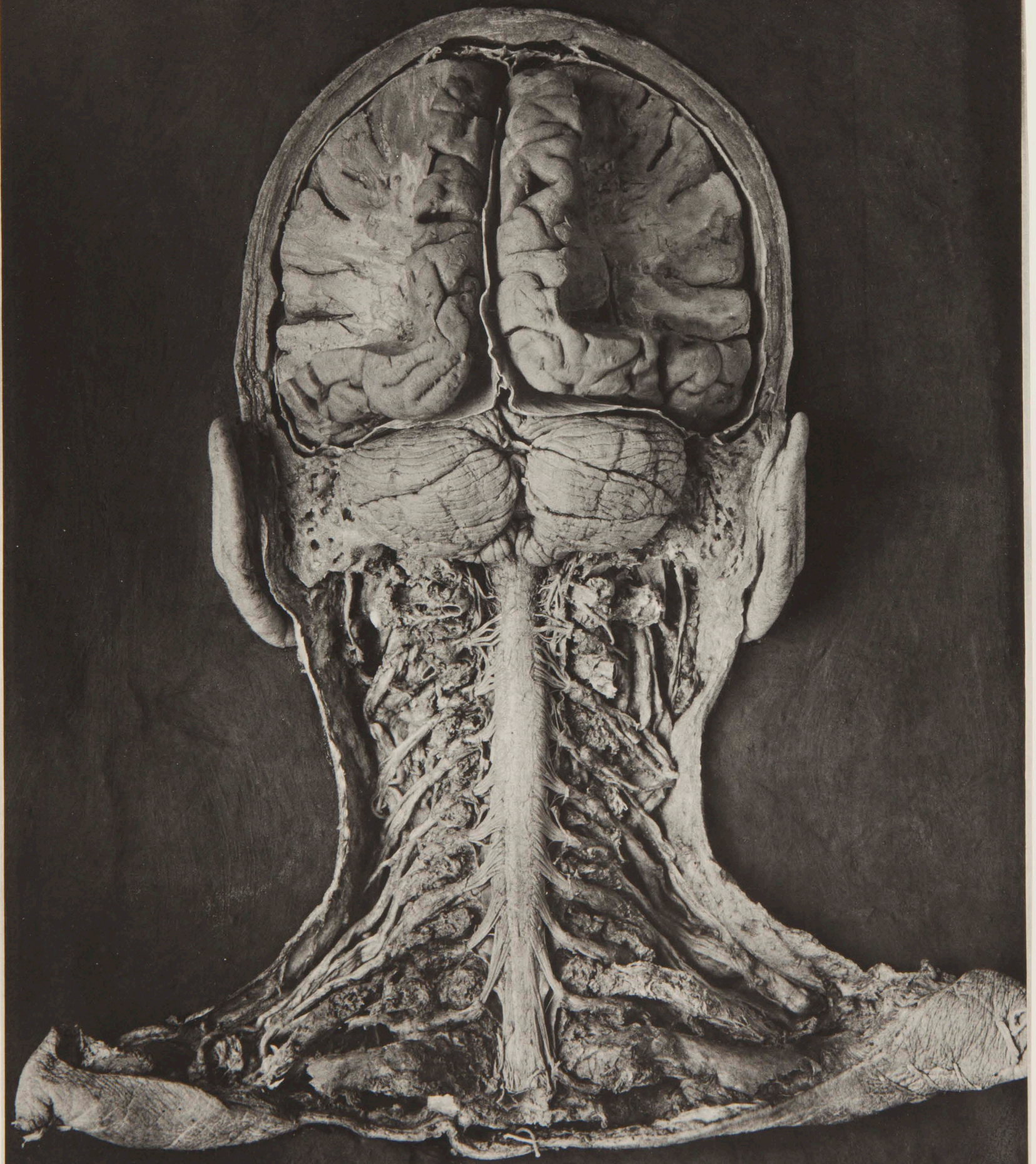









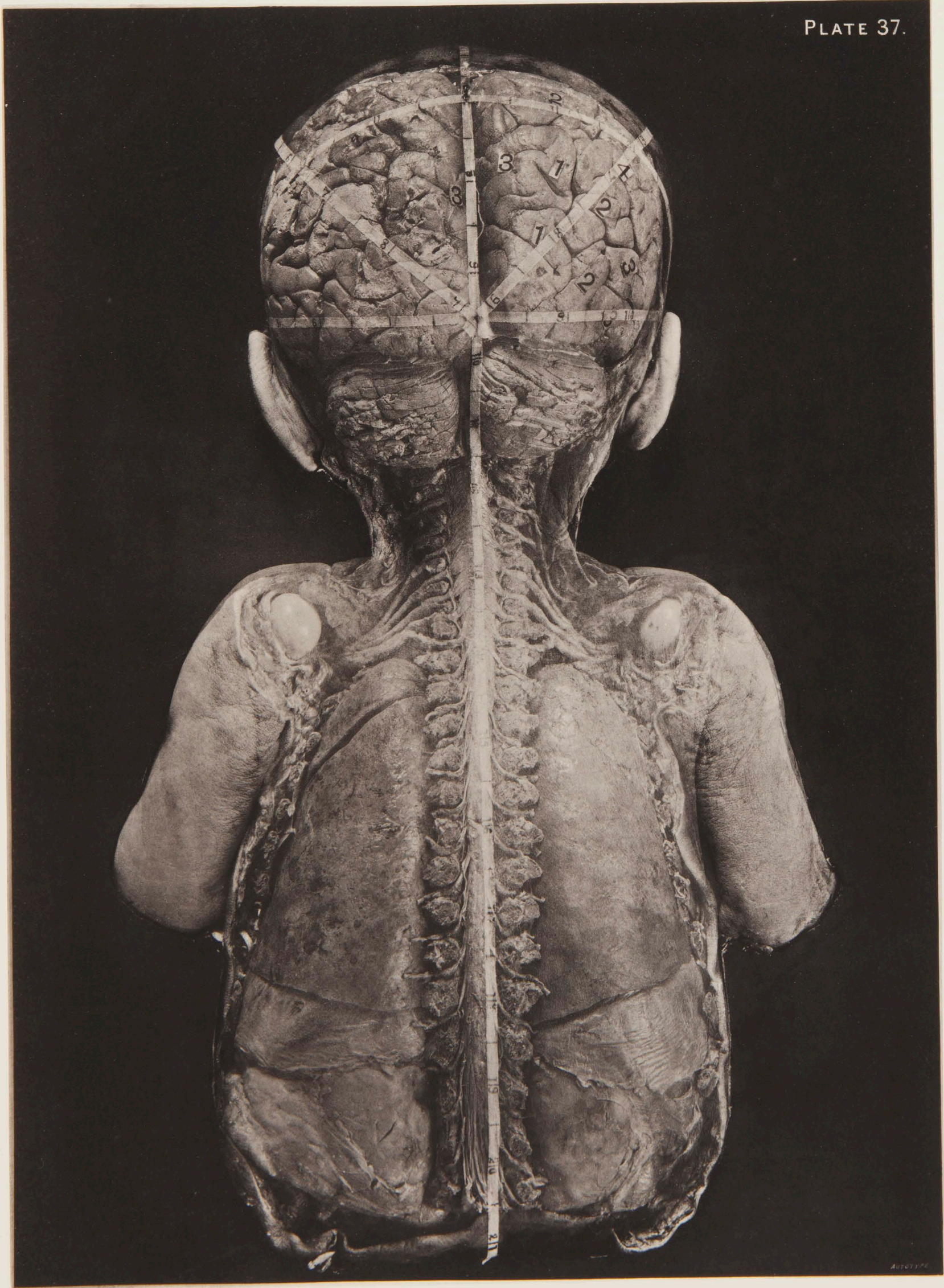




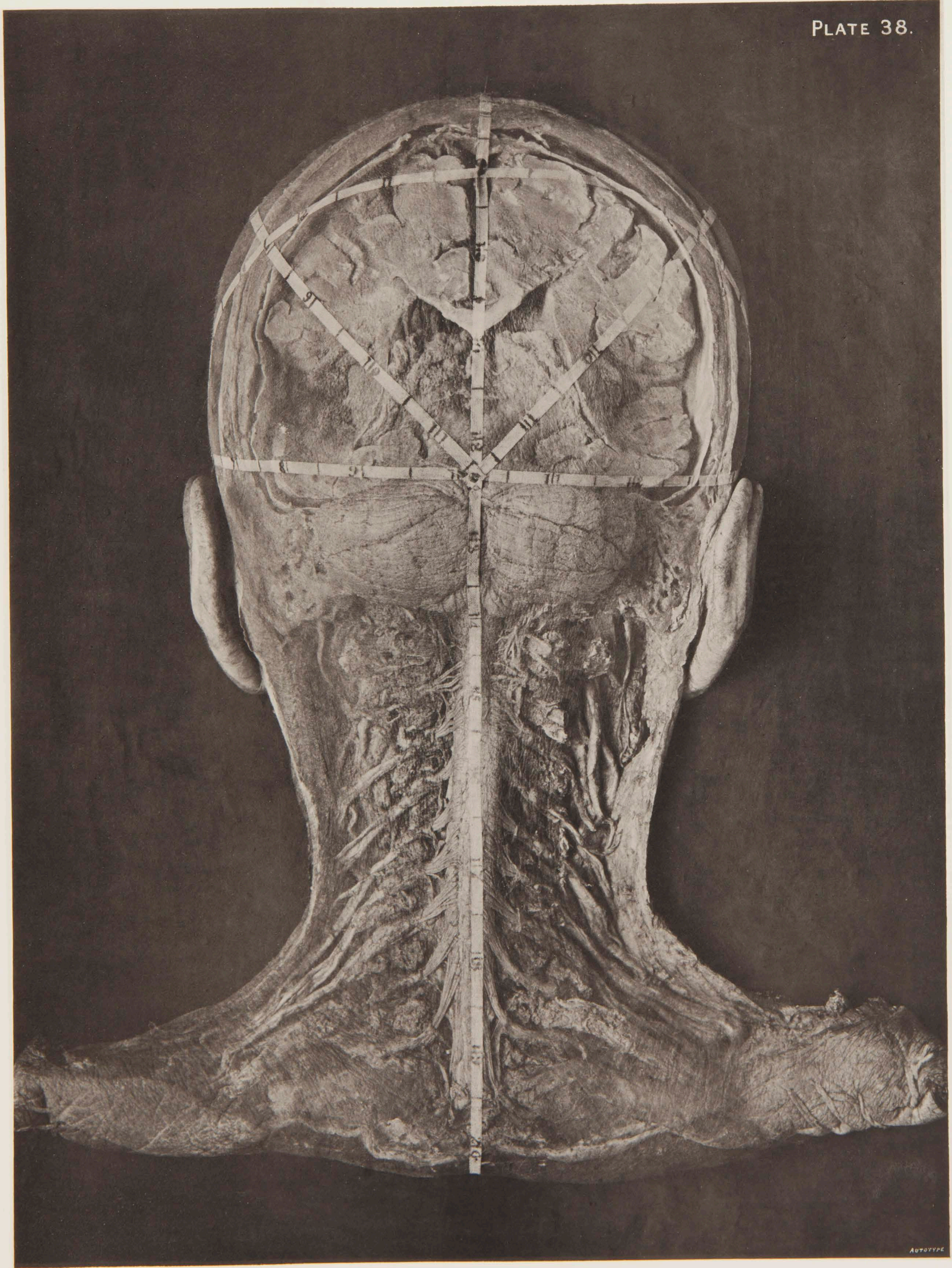













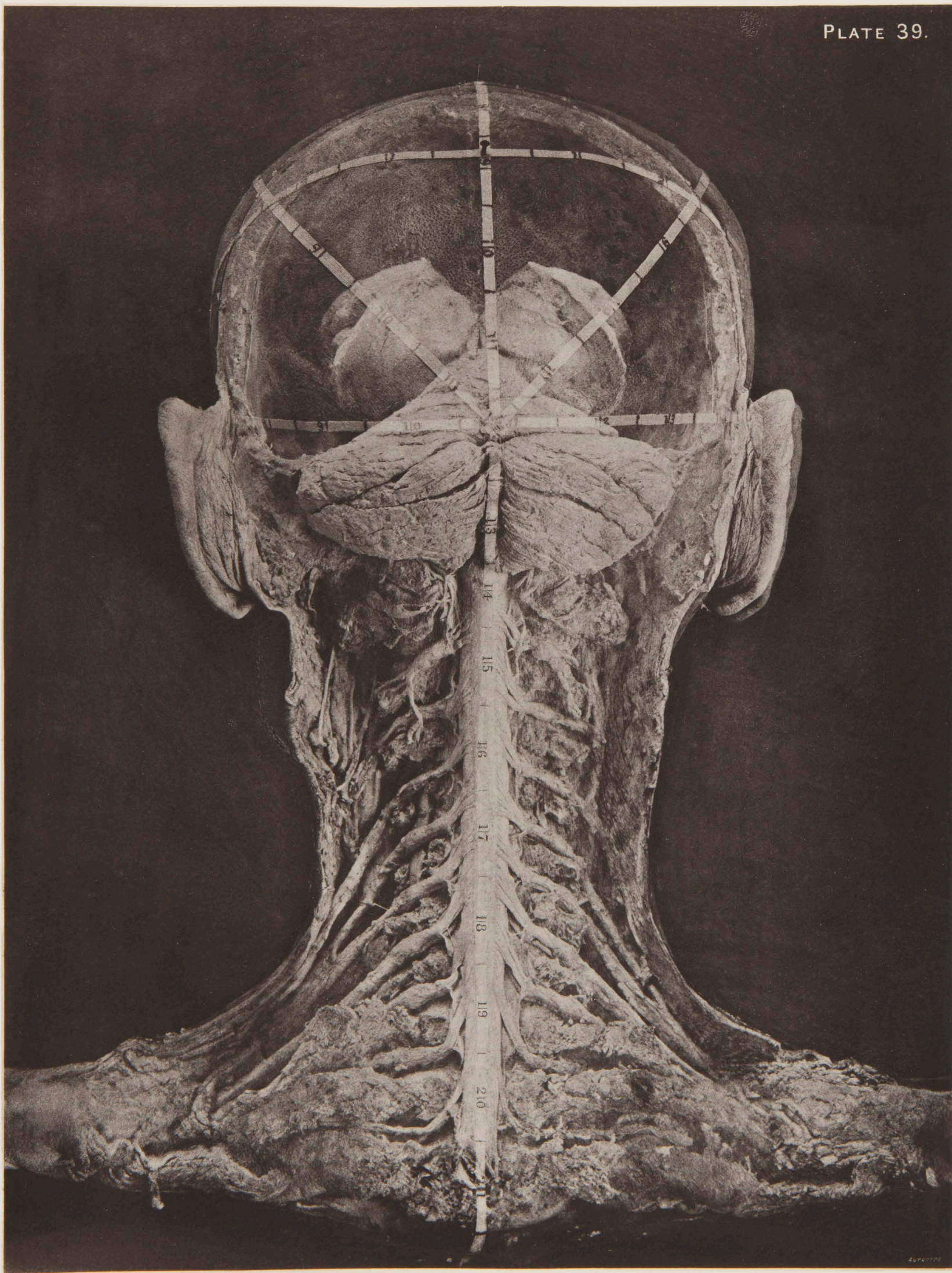





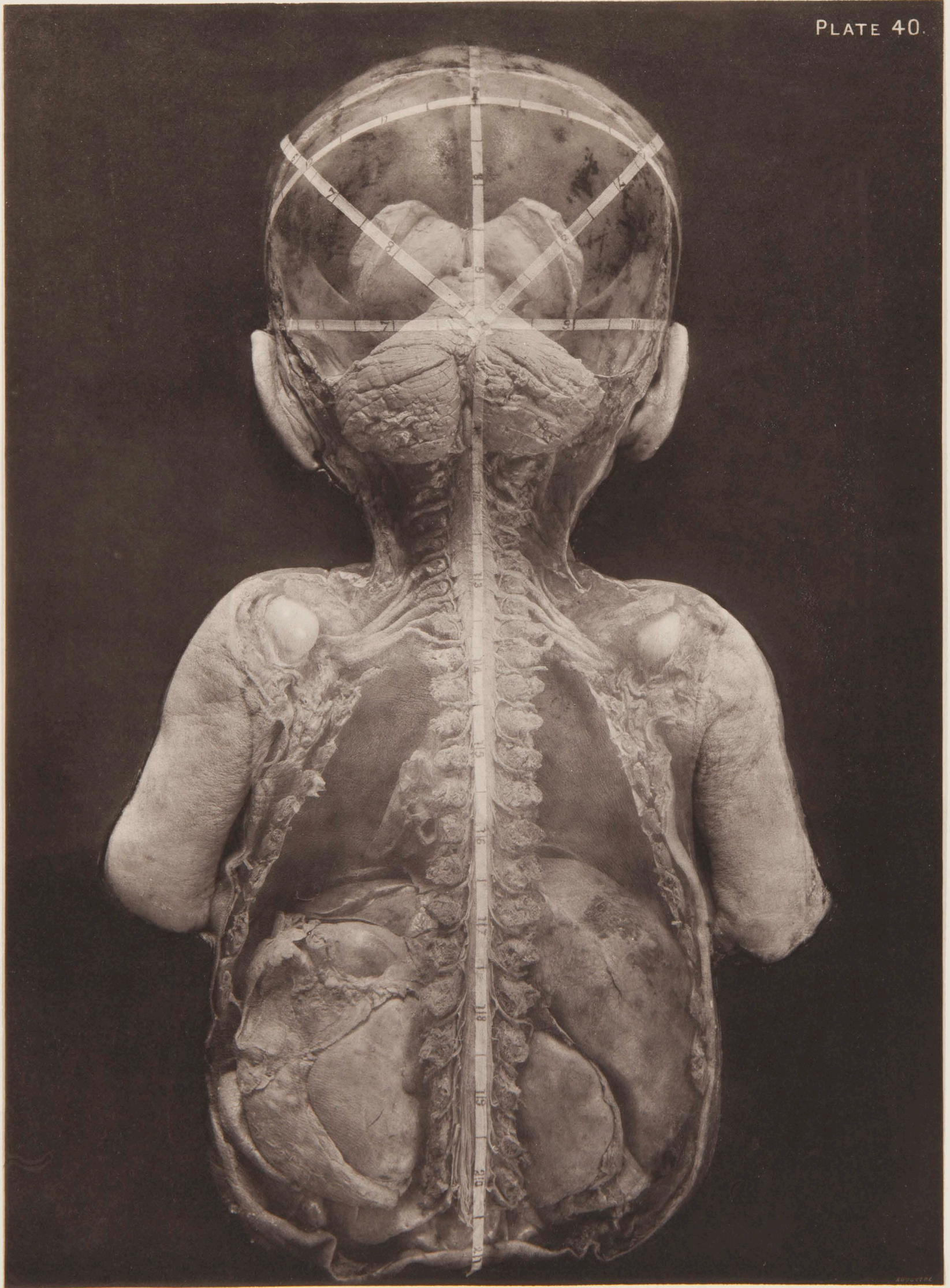













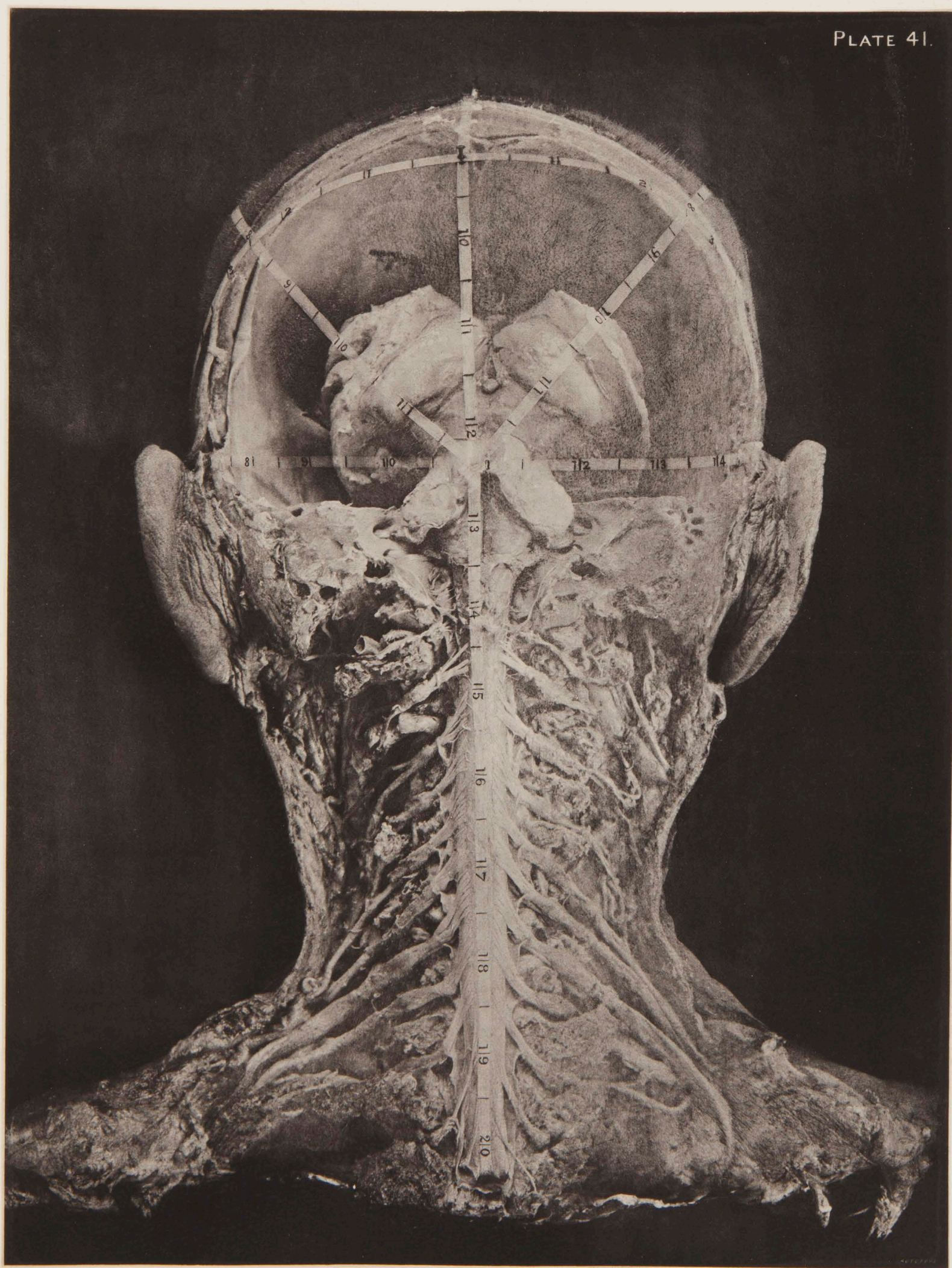
PLATE 40.










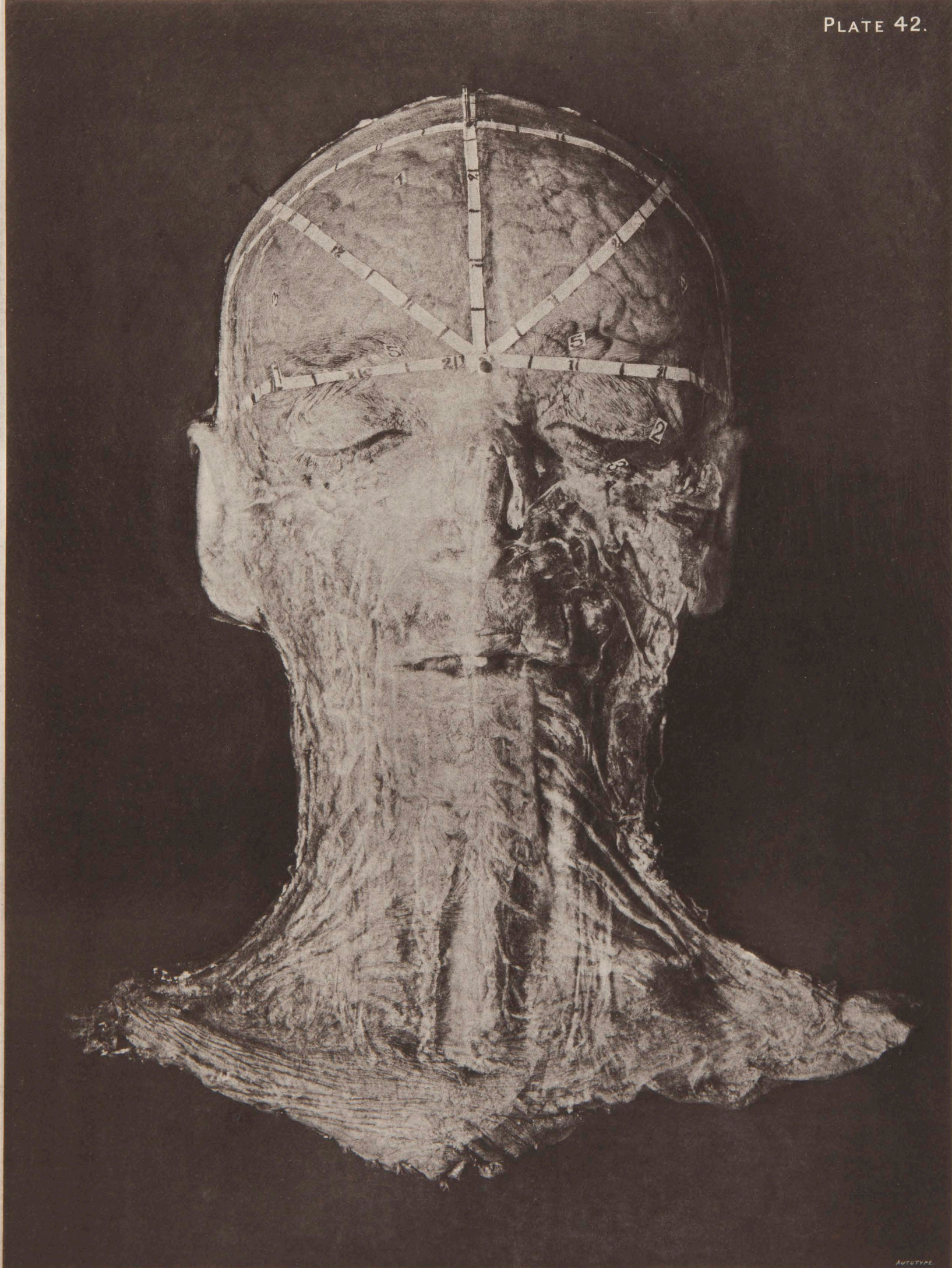







PLATE 42.




AUTOTYPE.















Accession no.  
JFF  
Author  
Fraser, Alec, 1853-1907  
Guide to operations  
on the brain.  
Call no. RD594  
19th CENT 1890F  
++



